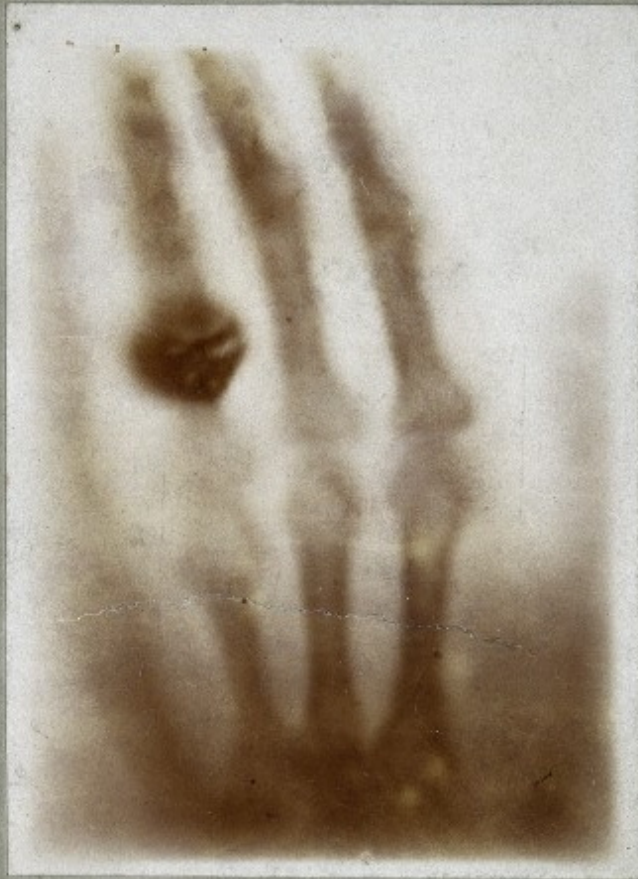

Cévní zobrazování a  
intervence: historie a  
perspektivy

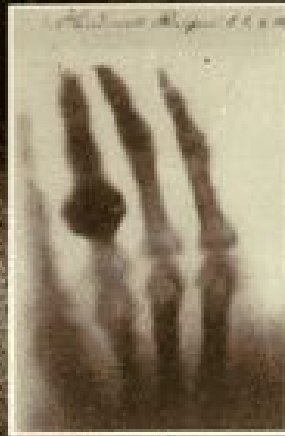
*Peregrin JH*



Hand mit Ringen.



PHYSIK. INSTITUT  
DER UNIVERSITÄT  
WÜRZBURG.

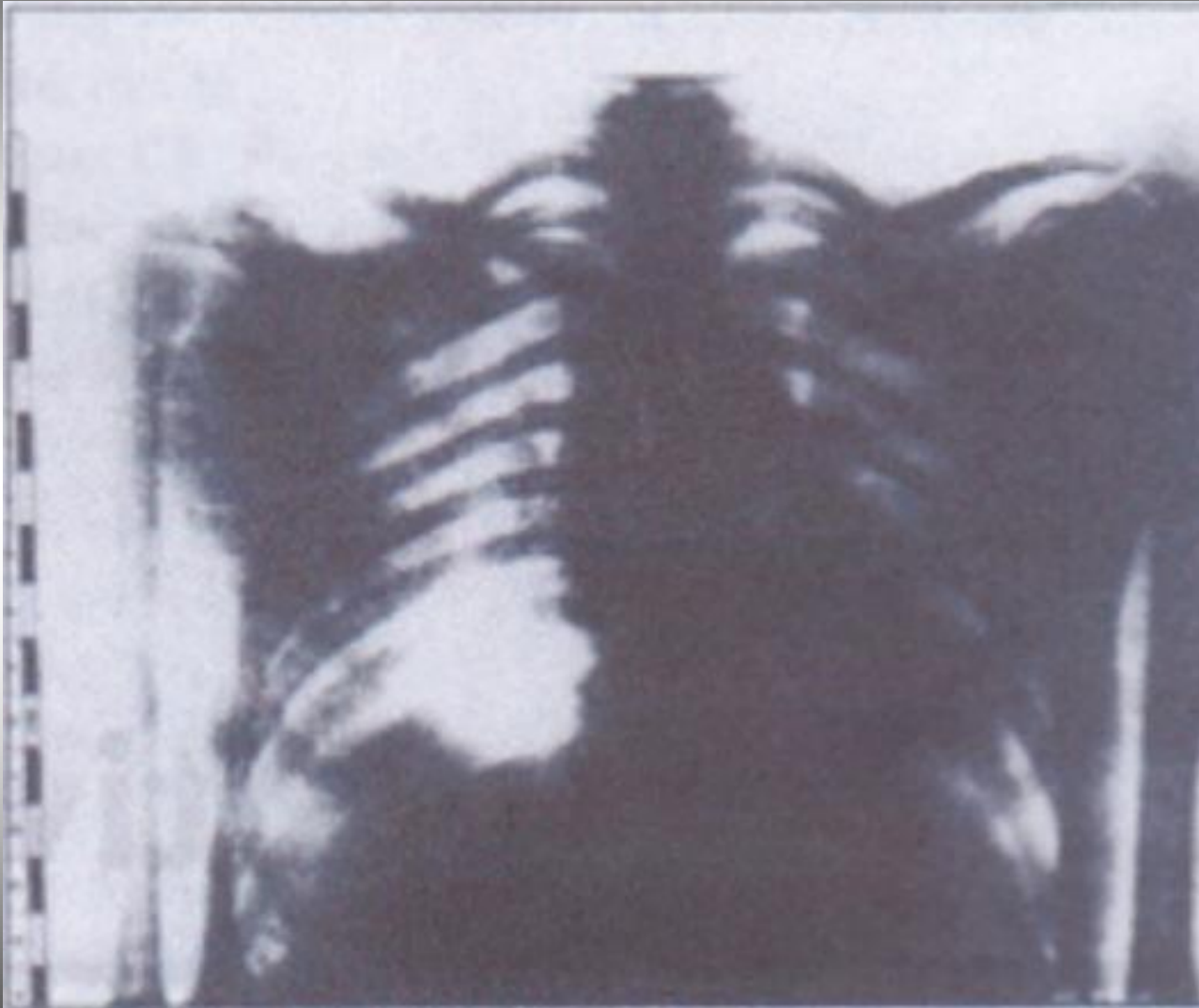




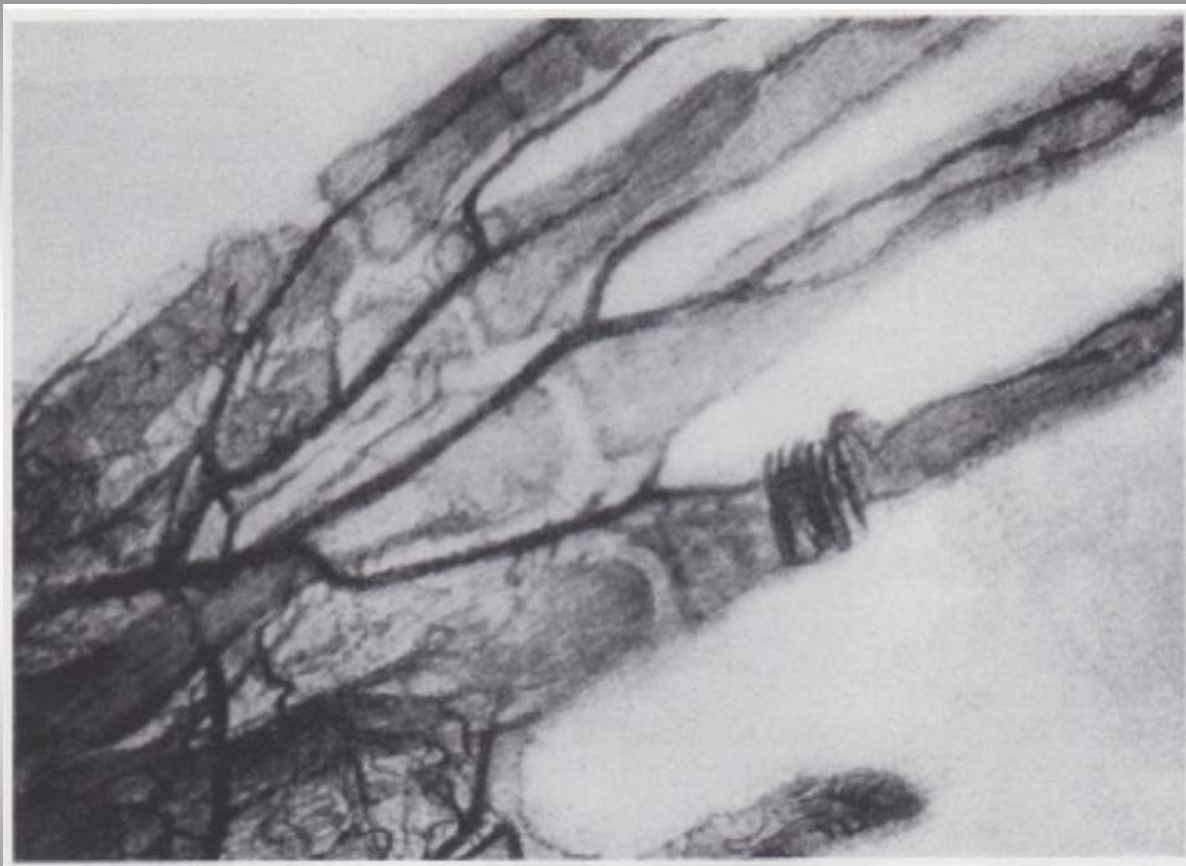



**1898**



# 1896



Haschek & Lindenthal

Amputovaná ruka

- Křída
- Sulfid rtuťnatý
- Vazelína

Teichmannova mixtura

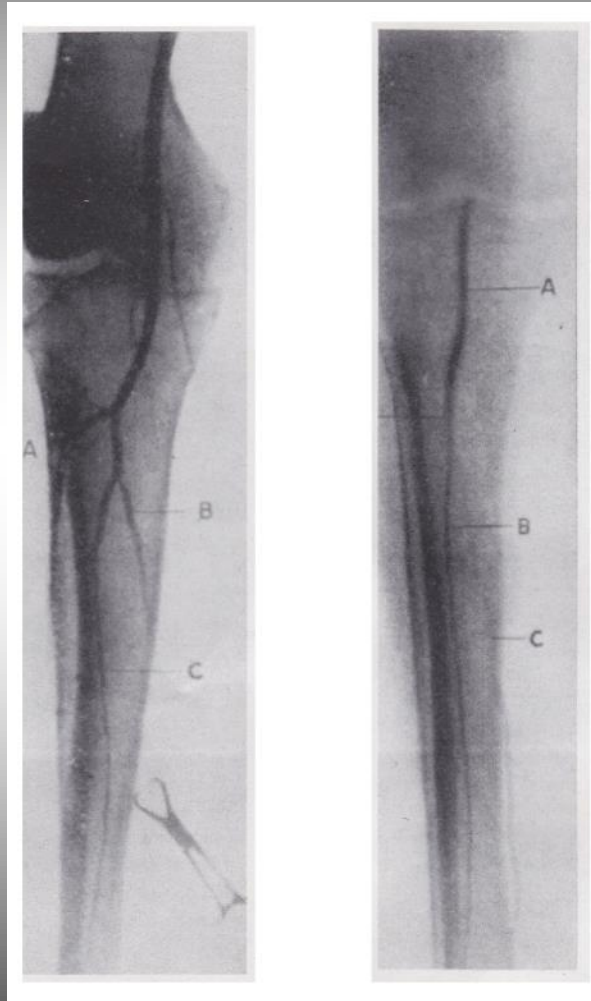
- Křída
- Oxid olovnato-  
olovičitý
- Petrolej

Vznik pojmu  
„kontrastní látka“

# *Historie angiografie a PTA*

- 1924 Brooks: Femorální AG (preparace)
- 1927 E. Moniz: Punkční karotická AG
- 1929 W. Forssmann: Zavedení katétru z kubitální žíly do pravého srdce
- 1929 R. dos Santos: Translumbální aortografie
- 1938 C. dos Santos: Punkční flebografie

**1924**



**Arteriografie**

**Brooks**

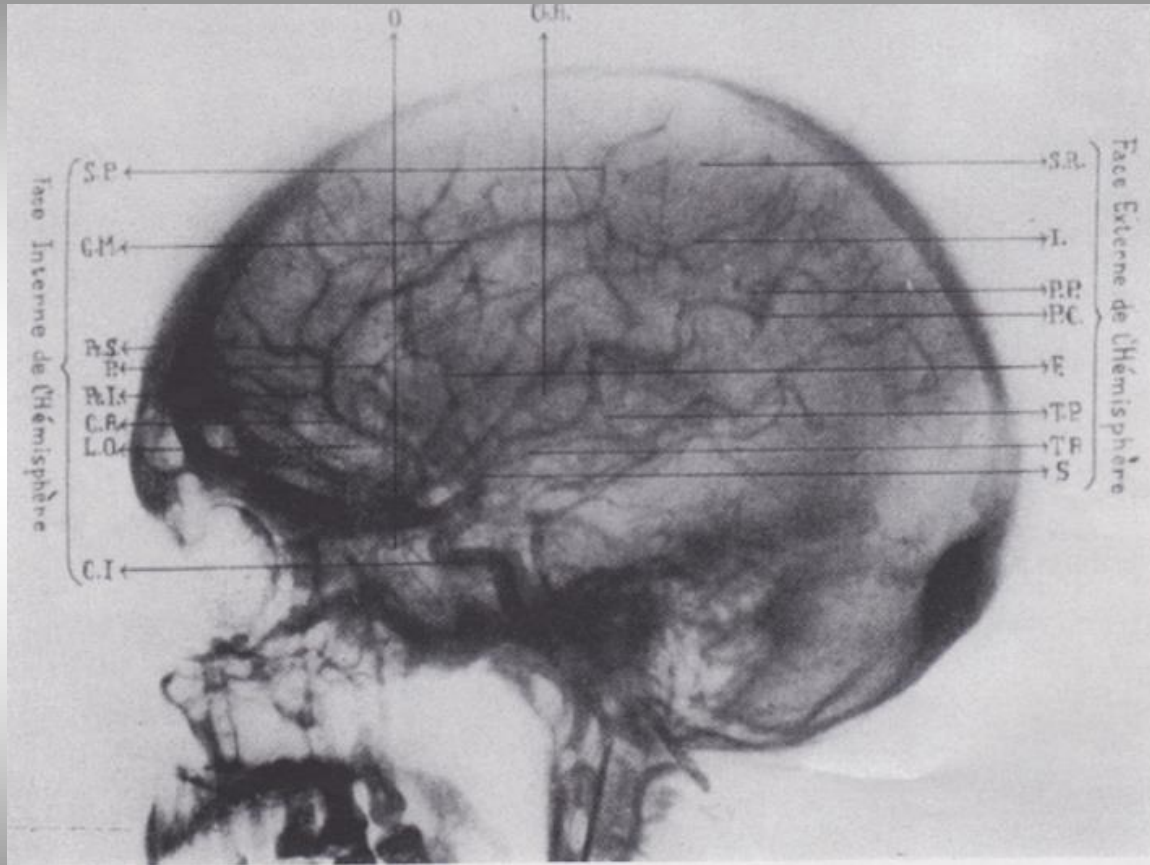
**Jodid sodný**



# *Historie angiografie a PTA*

- 1924 Brooks: Femorální AG (preparace)
- 1927 E. Moniz: Punkční karotická AG
- 1929 E. Forssmann: Zavedení katétru z kubitální žíly do pravého srdce
- 1929 R. dos Santos: Translumbální aortografie
- 1938 C. dos Santos: Punkční flebografie

# 1927

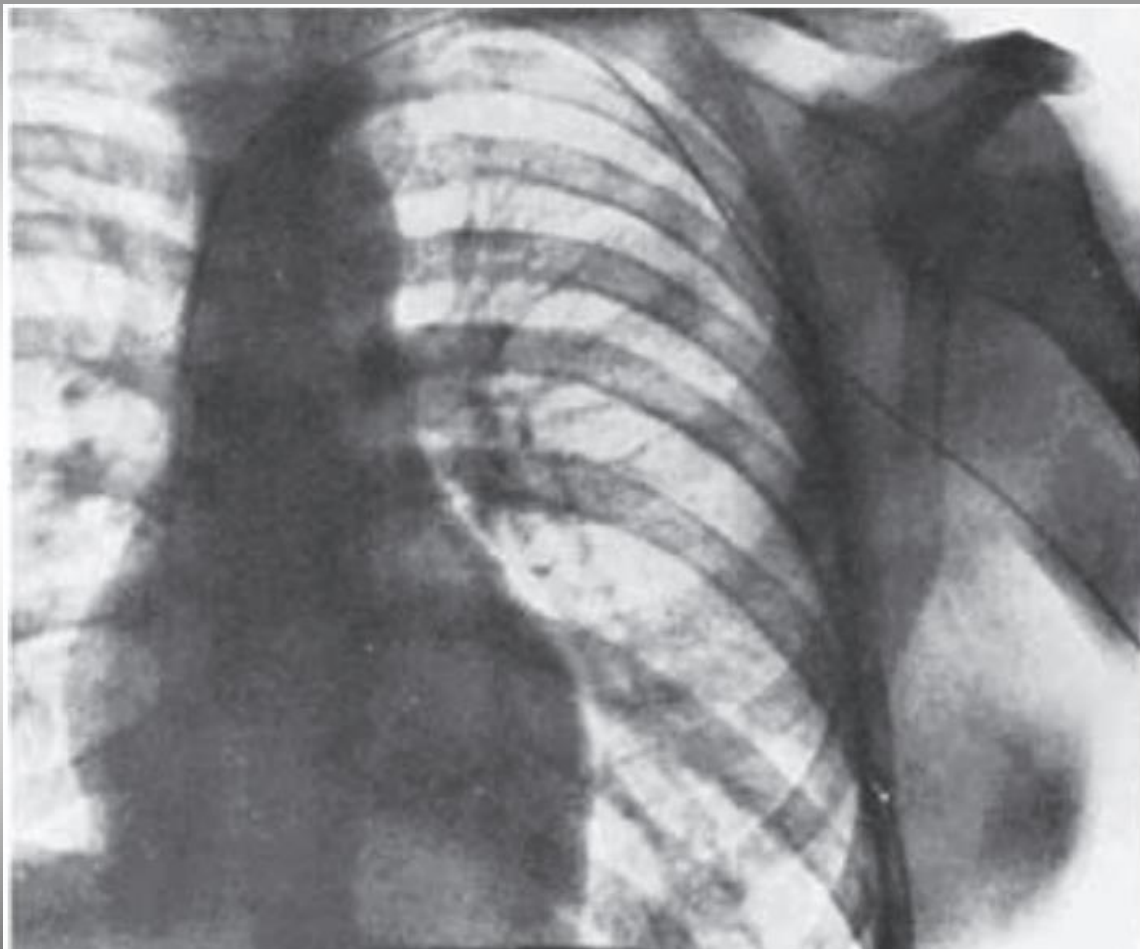


**Punkční karotická  
angiografie**

# *Historie angiografie a PTA*

- 1924 Brooks: Femorální AG (preparace)
- 1927 E. Moniz: Punkční karotická AG
- 1929 W. Forssmann: Zavedení katétru z kubitální žíly do pravého srdce
- 1929 R. dos Santos: Translumbální aortografie
- 1938 C. dos Santos: Punkční flebografie

**1929**

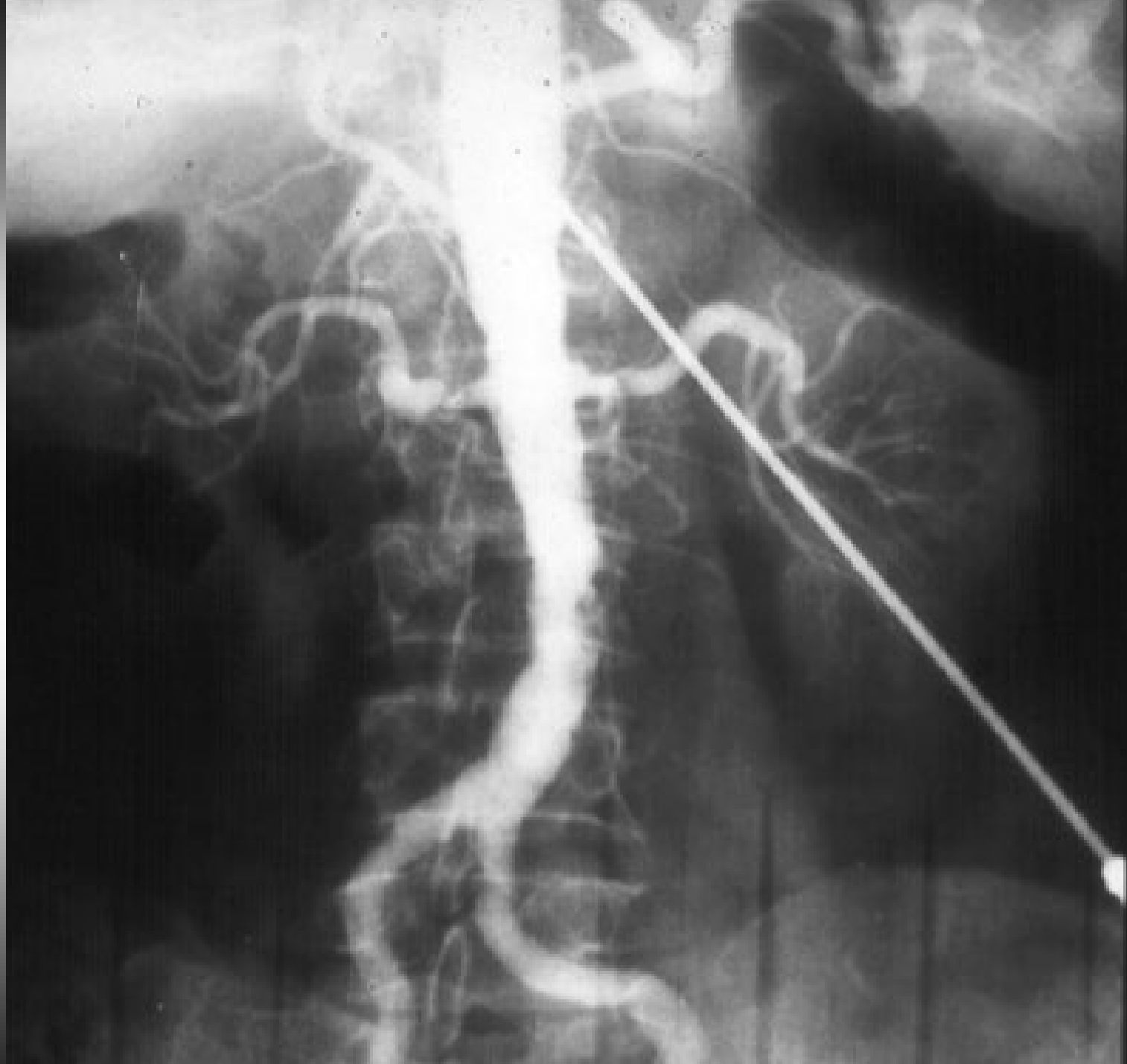


**Zavedení katetru  
z kubitální žíly  
do pravé síně**



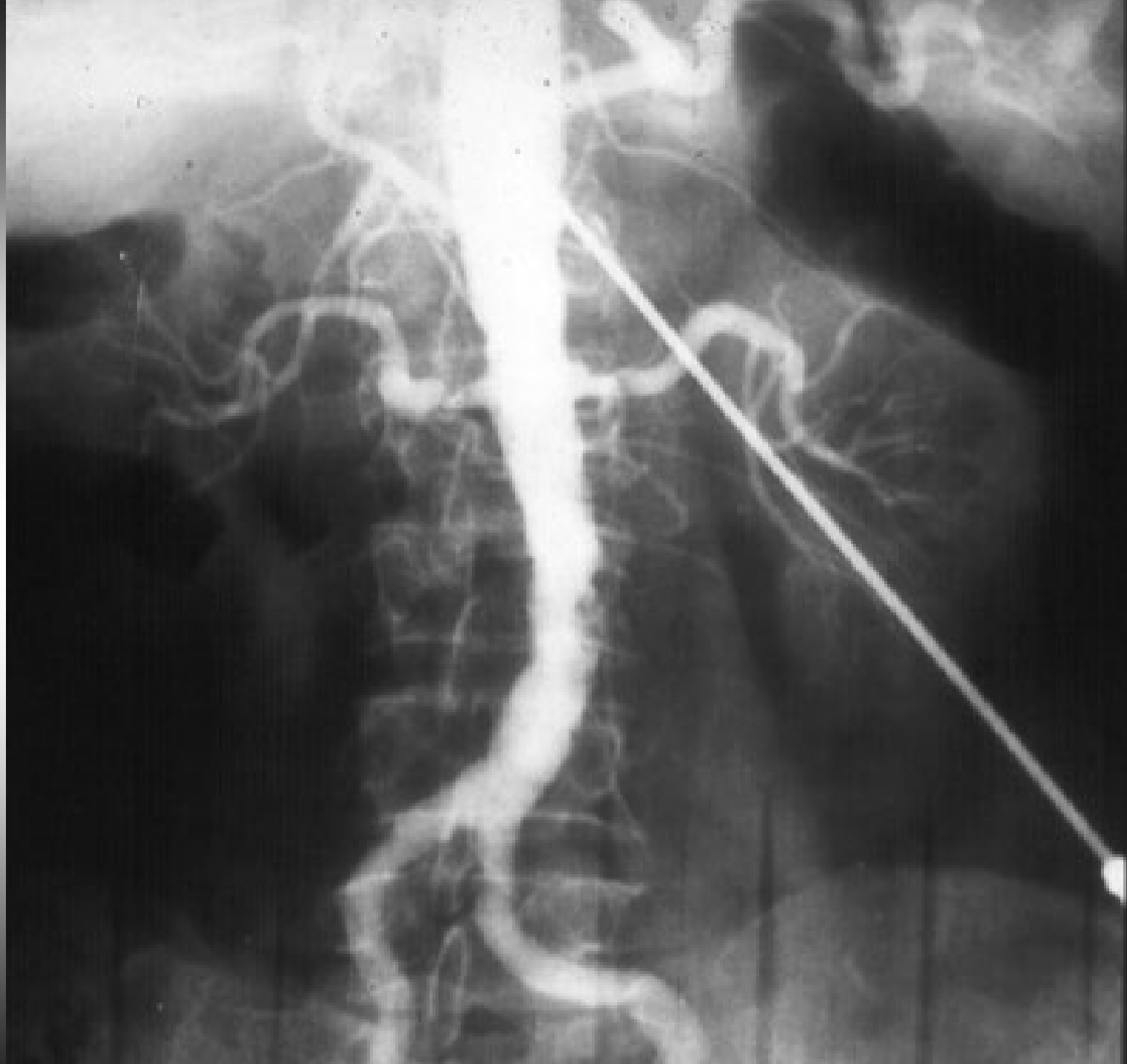
# *Historie angiografie a PTA*

- 1924 Brooks: Femorální AG (preparace)
- 1927 E. Moniz: Punkční karotická AG
- 1929 W. Forssmann: Zavedení katétru z kubitální žíly do pravého srdce
- 1929 R. dos Santos: Translumbální aortografie
- 1938 C. dos Santos: Punkční flebografie





Rubyblossom



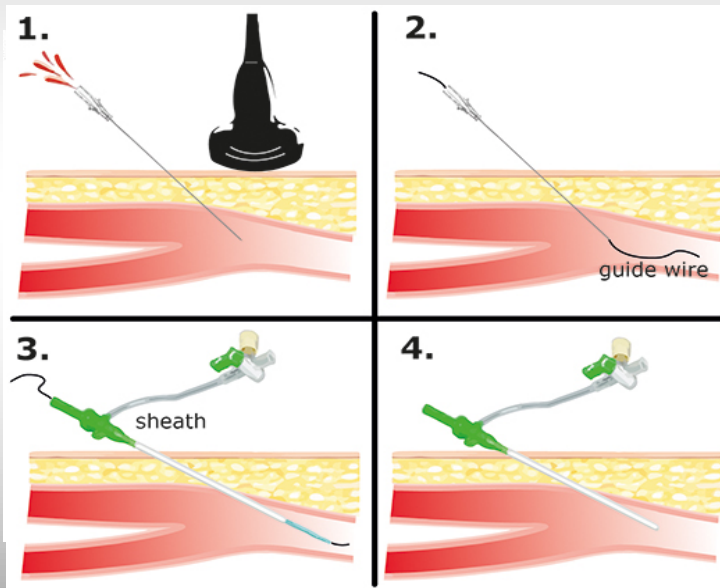


# *Historie angiografie a PTA*

- 1953 Seldinger: Perkutánní zavedení katétru do tepny punkční technikou
- 1964 Dotter: Transluminální angioplastika koaxiální cévkou
- 1974 Grüntzig: Transluminální angioplastika balónkovou cévkou
- 1980→ Stenty, mechanická rekanalizační zařízení, stentgrafty, TIPS

# Perkutánní přístup 1953


> 4385 citací

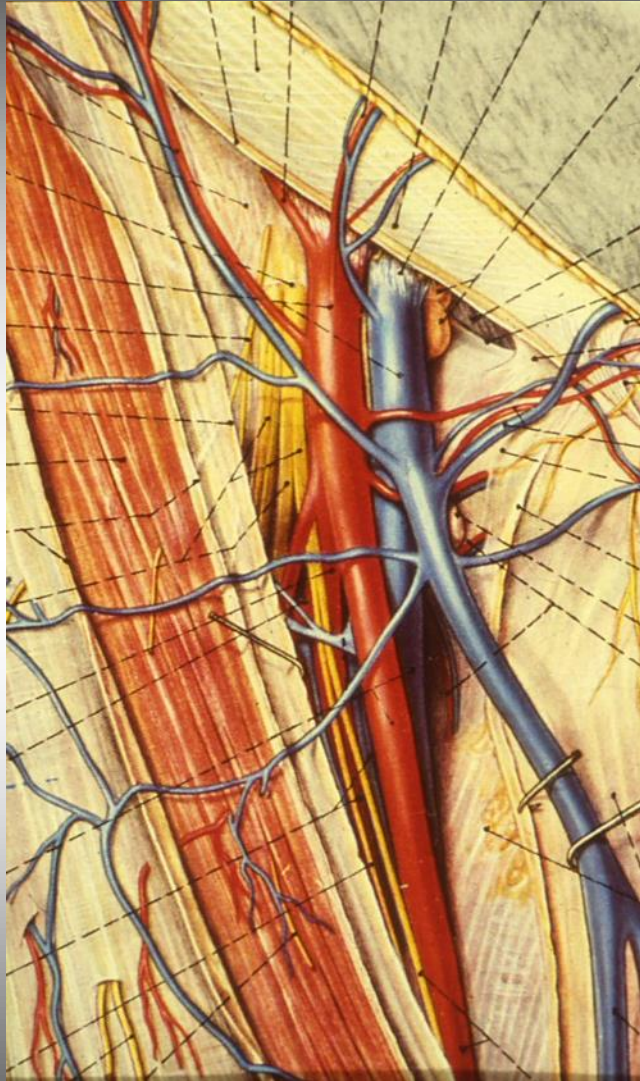


Sven Ivar Seldinger

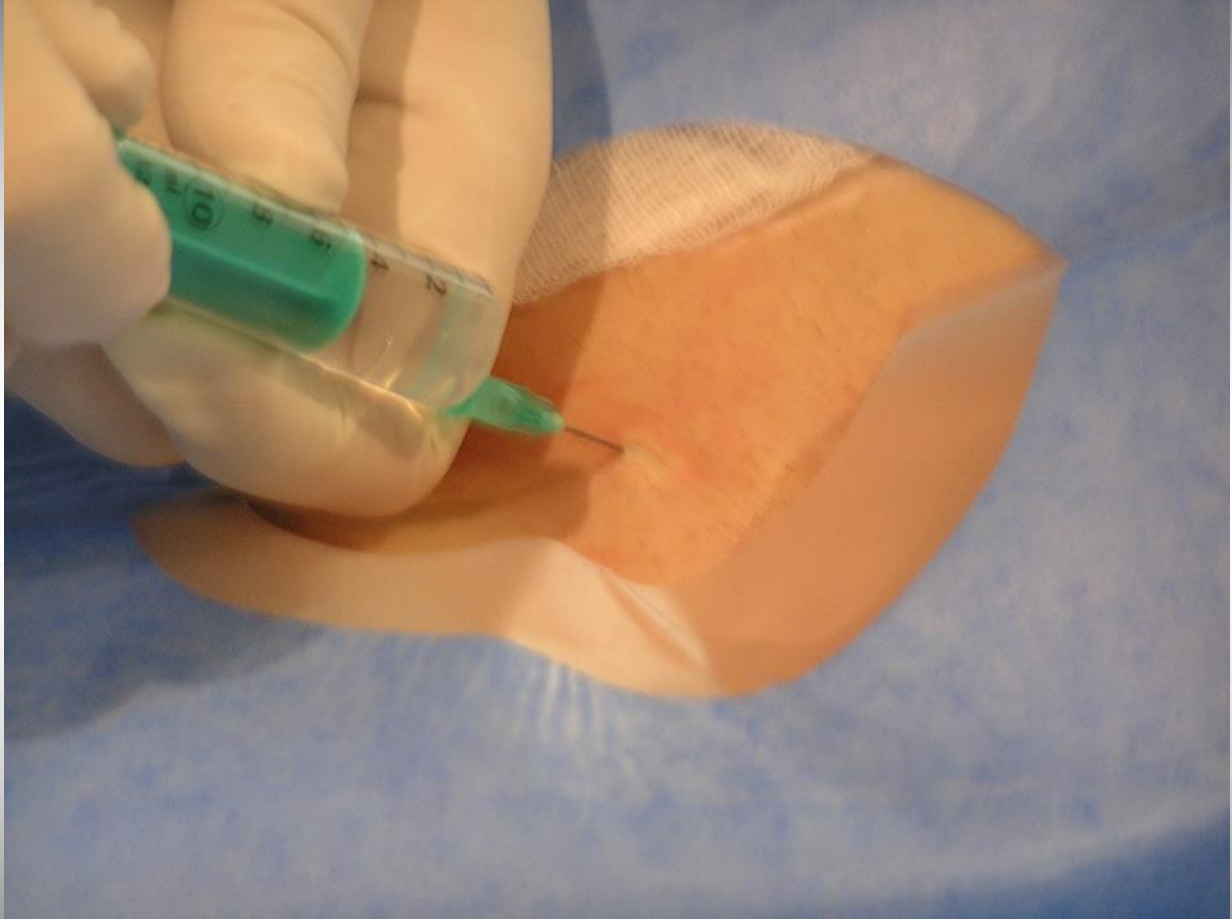


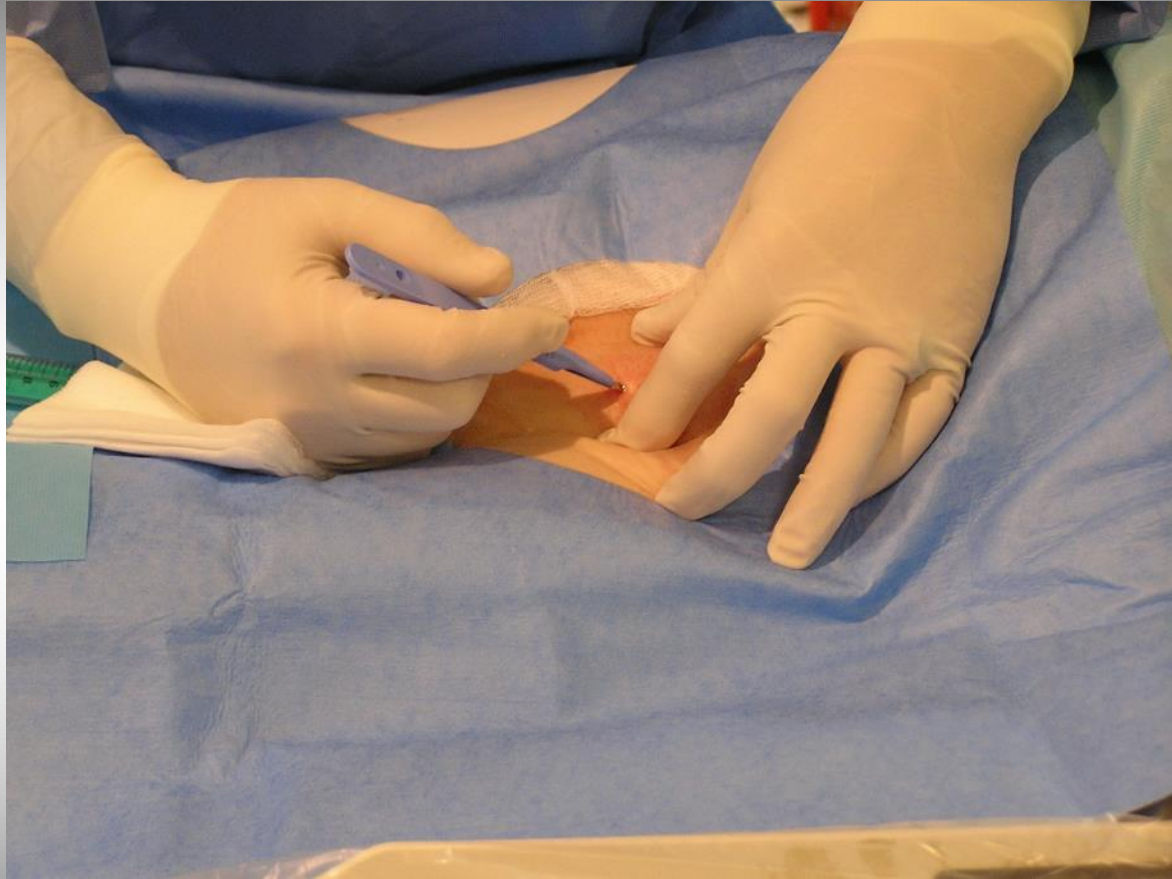Seldinger SI. "Catheter replacement of the needle in percutaneous arteriography; a new technique," *Acta Radiologica* 39, no. 5 (May 1953): 368-376

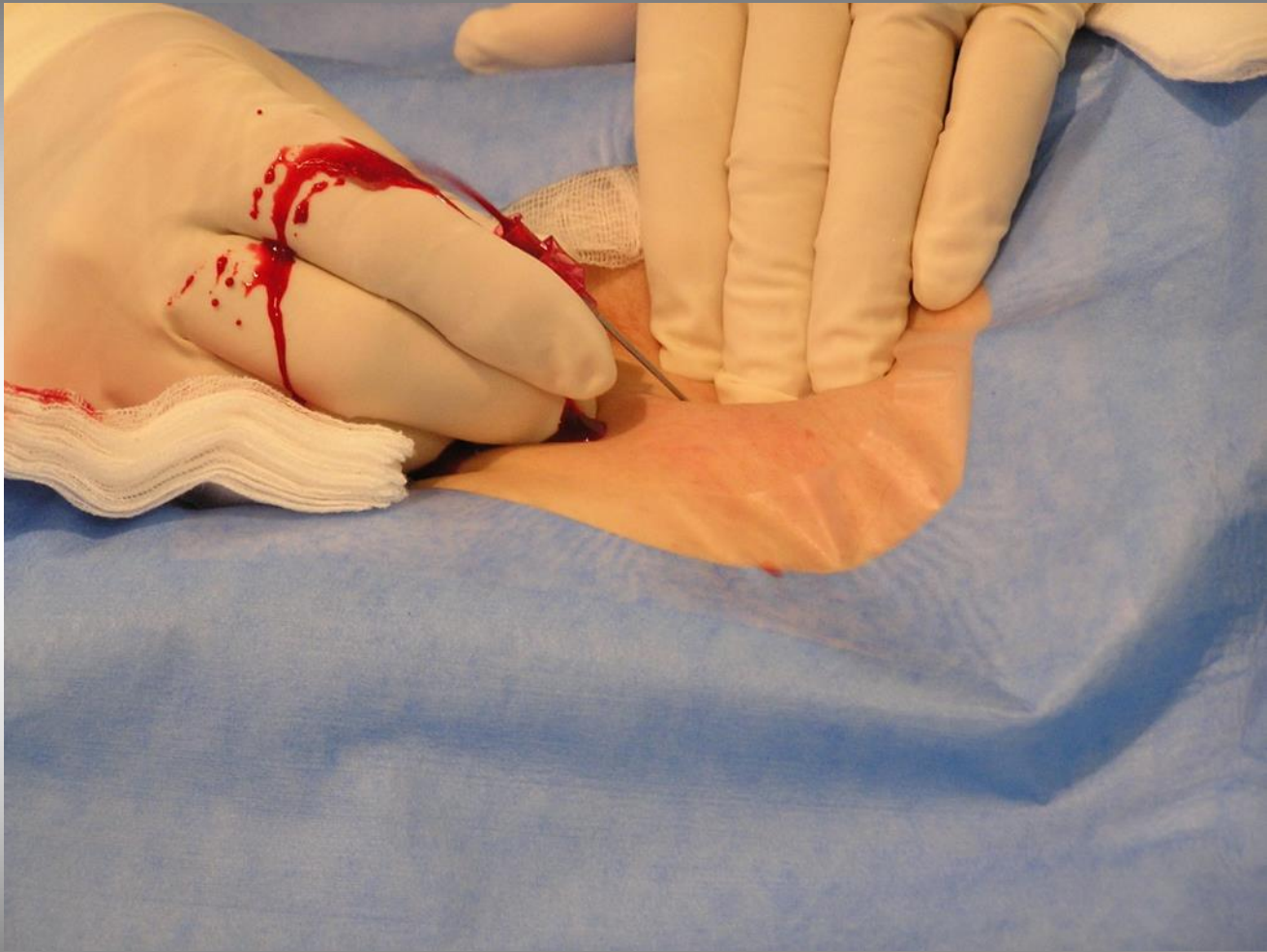


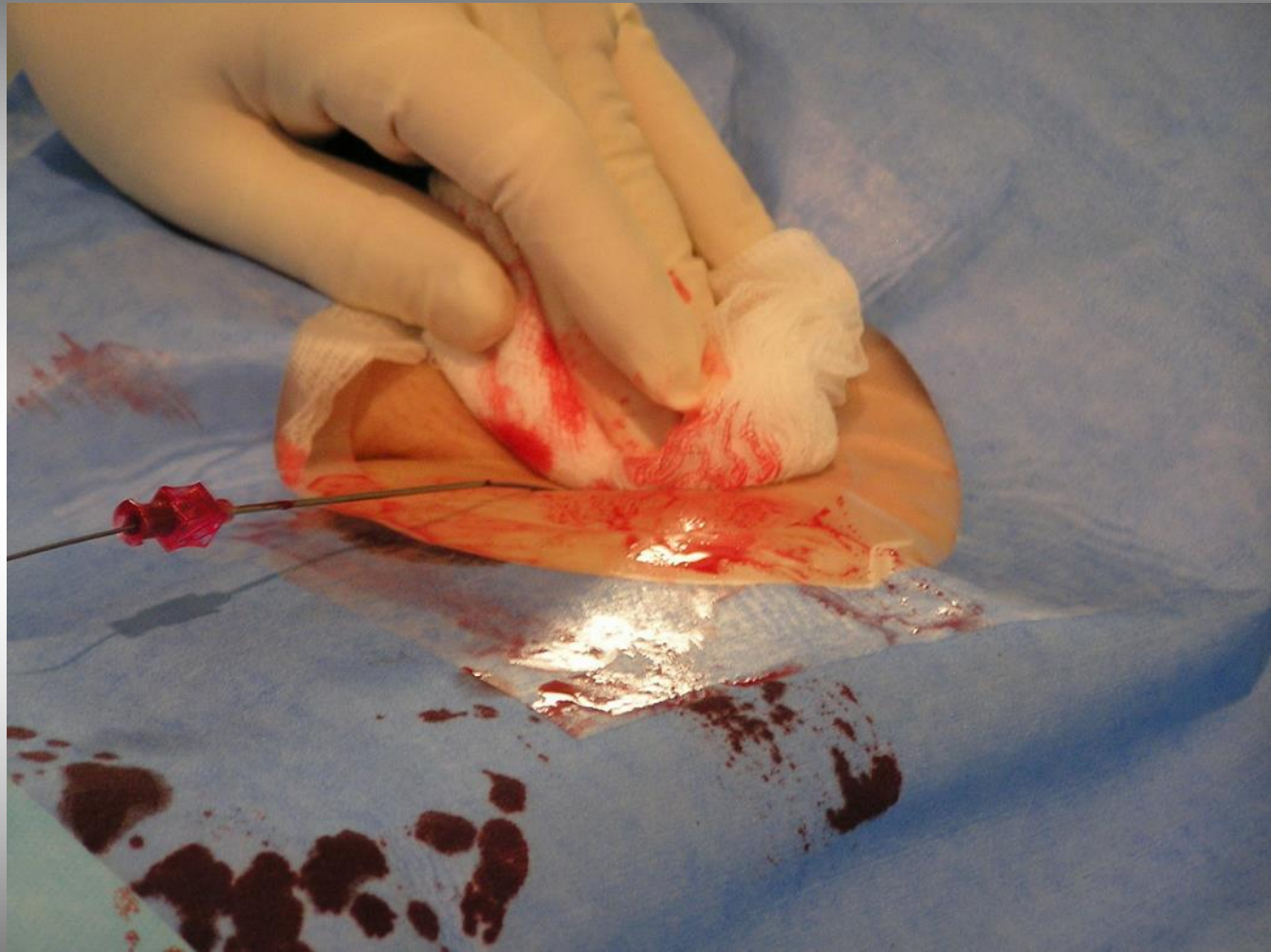


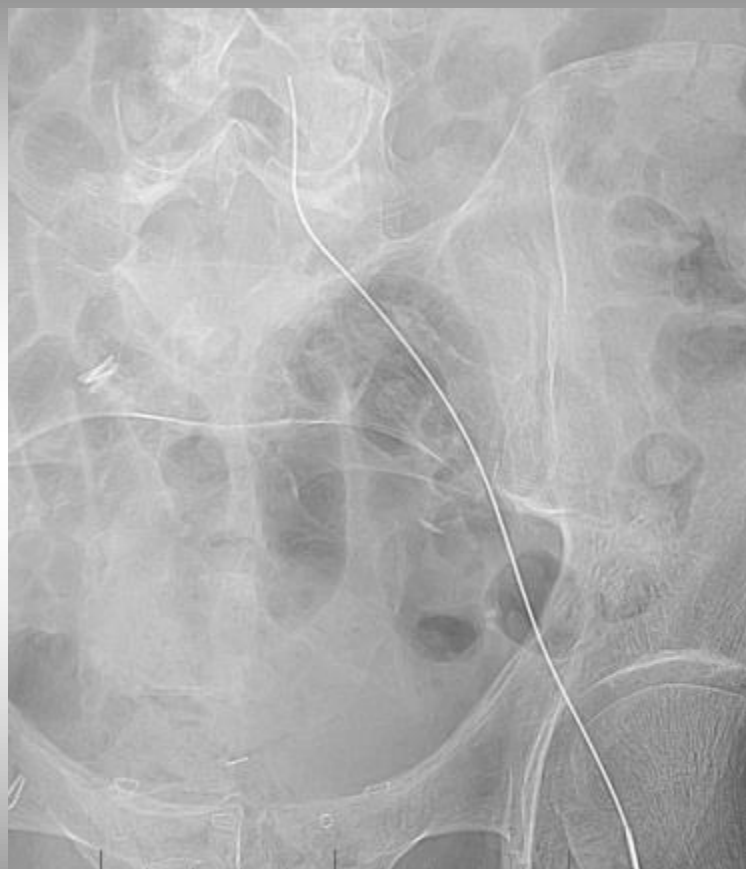




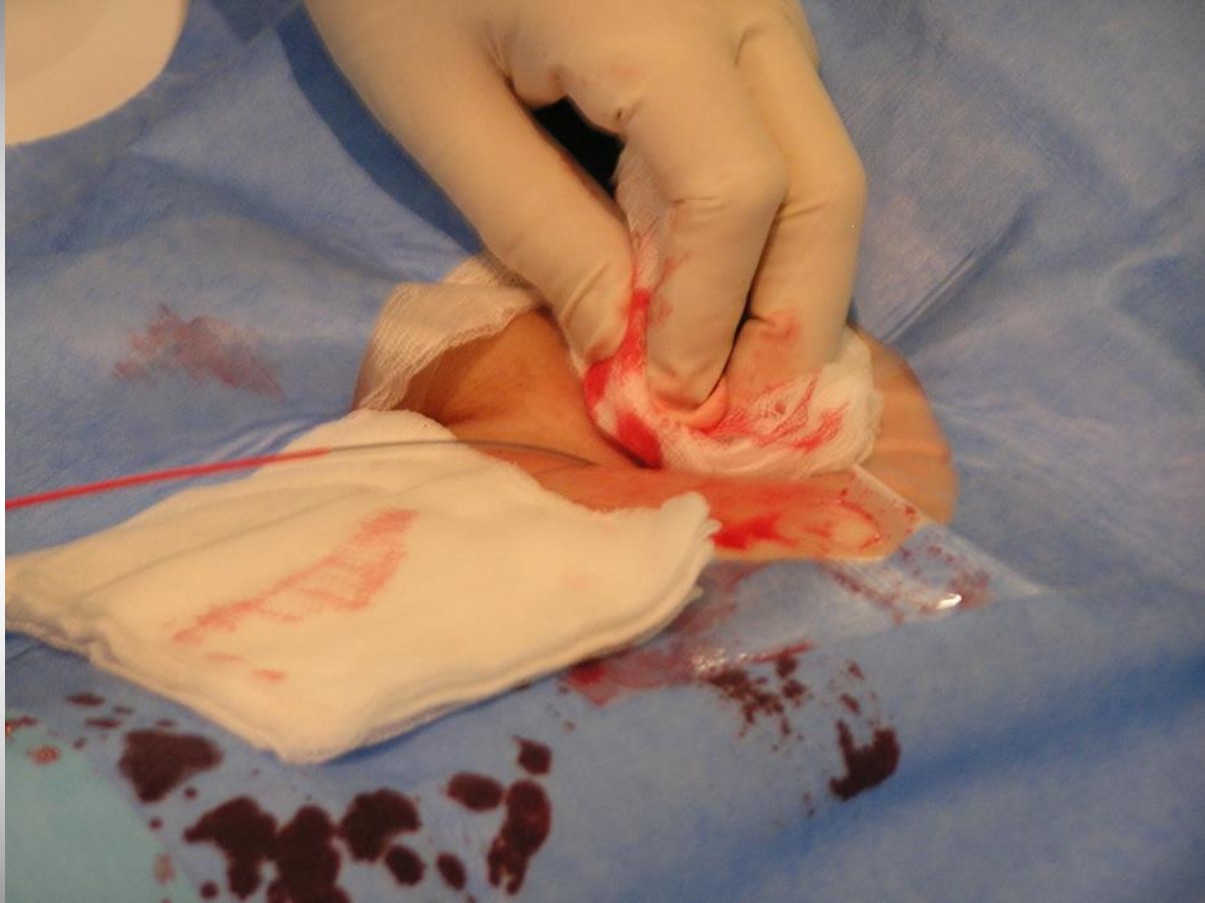


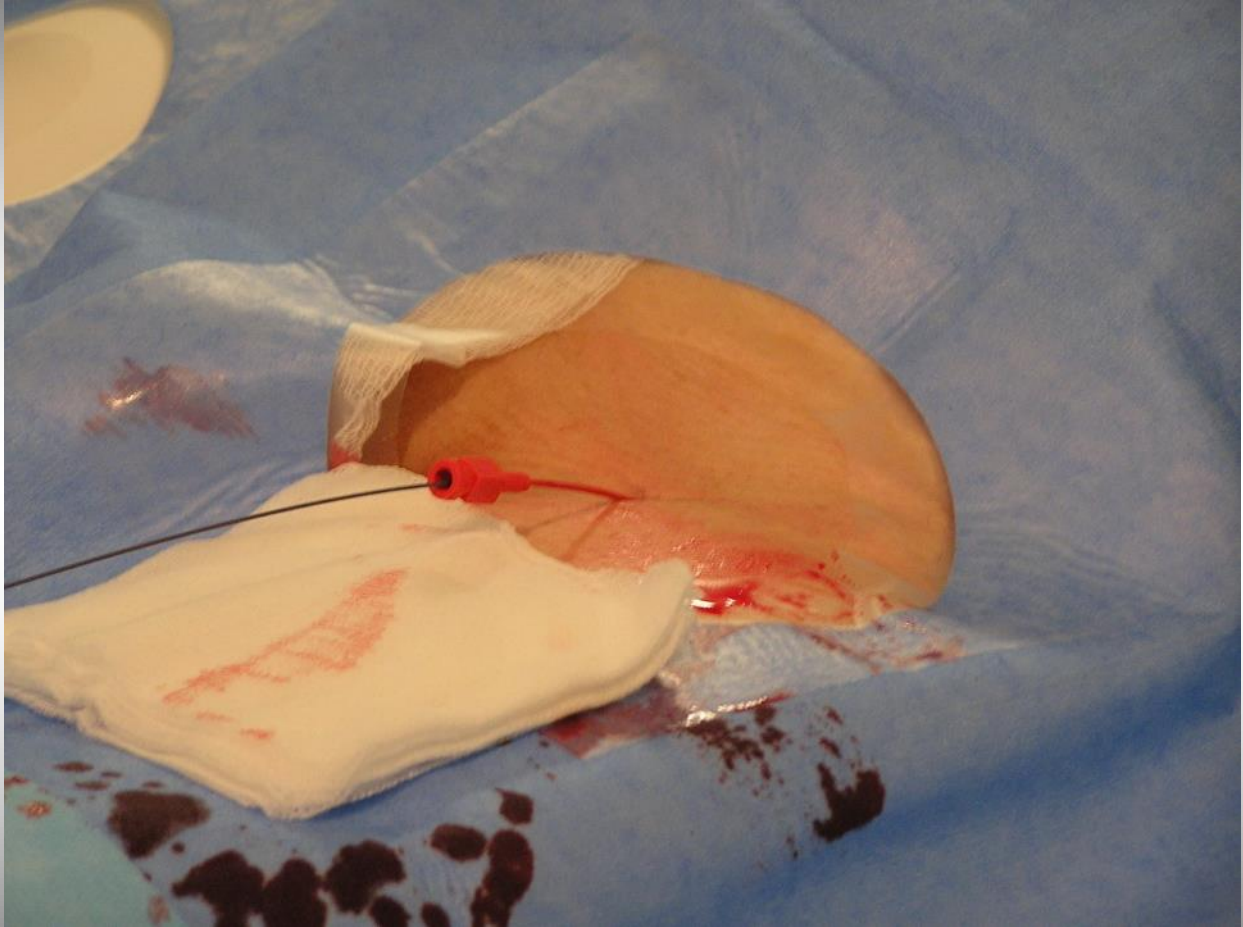




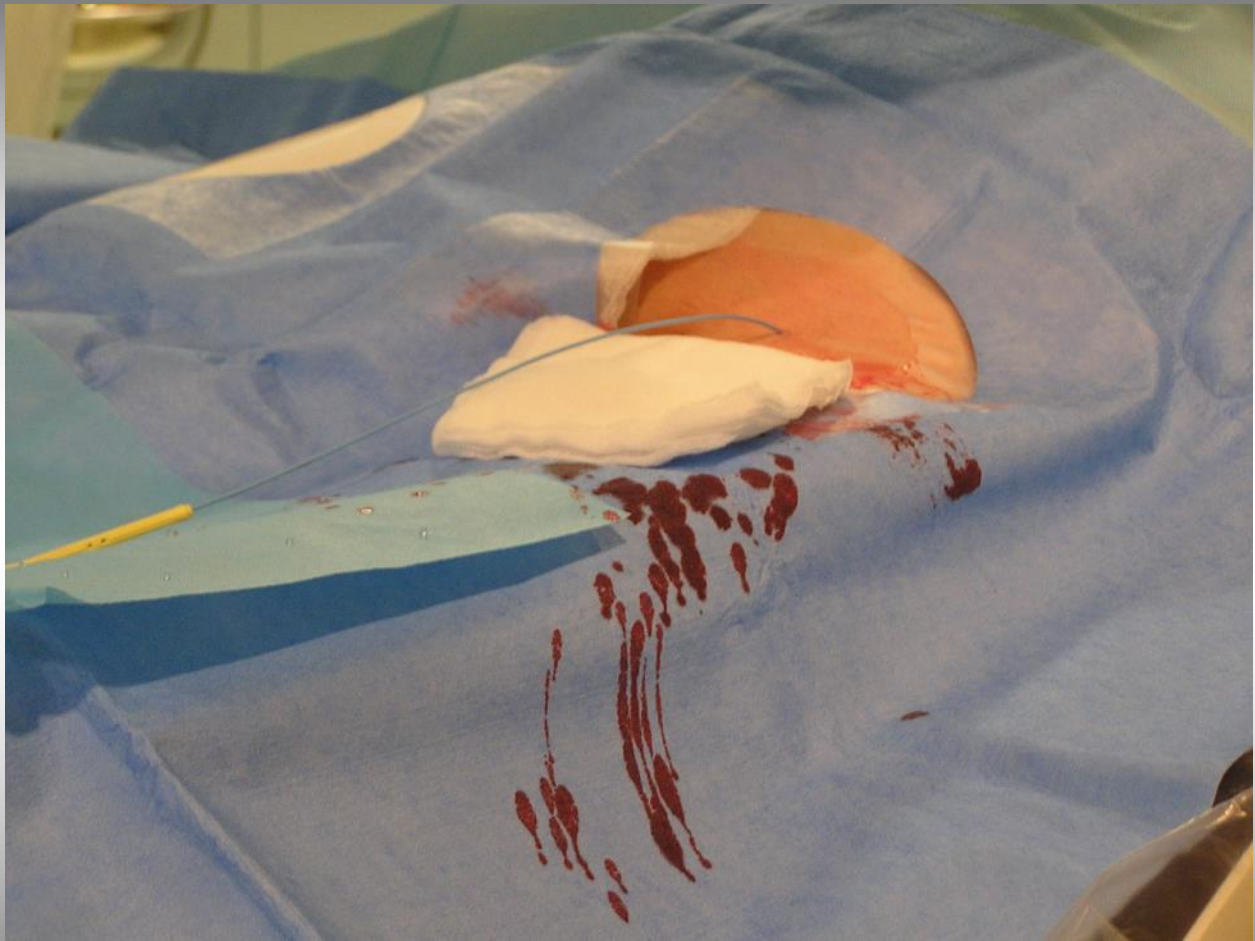

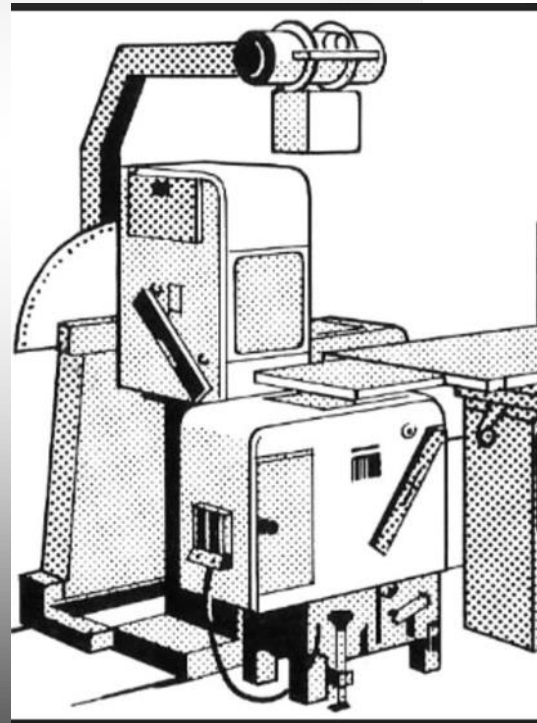
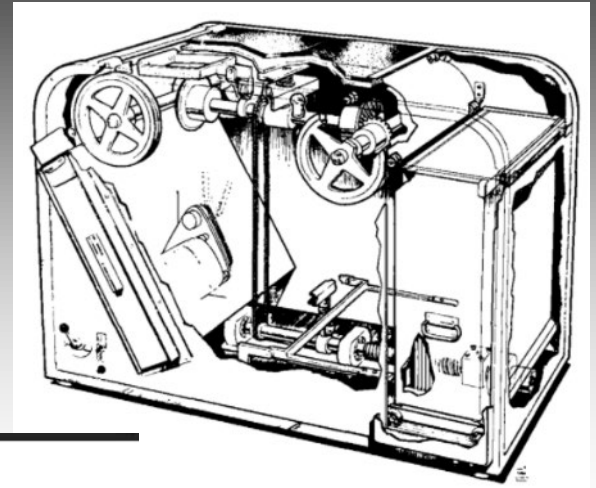



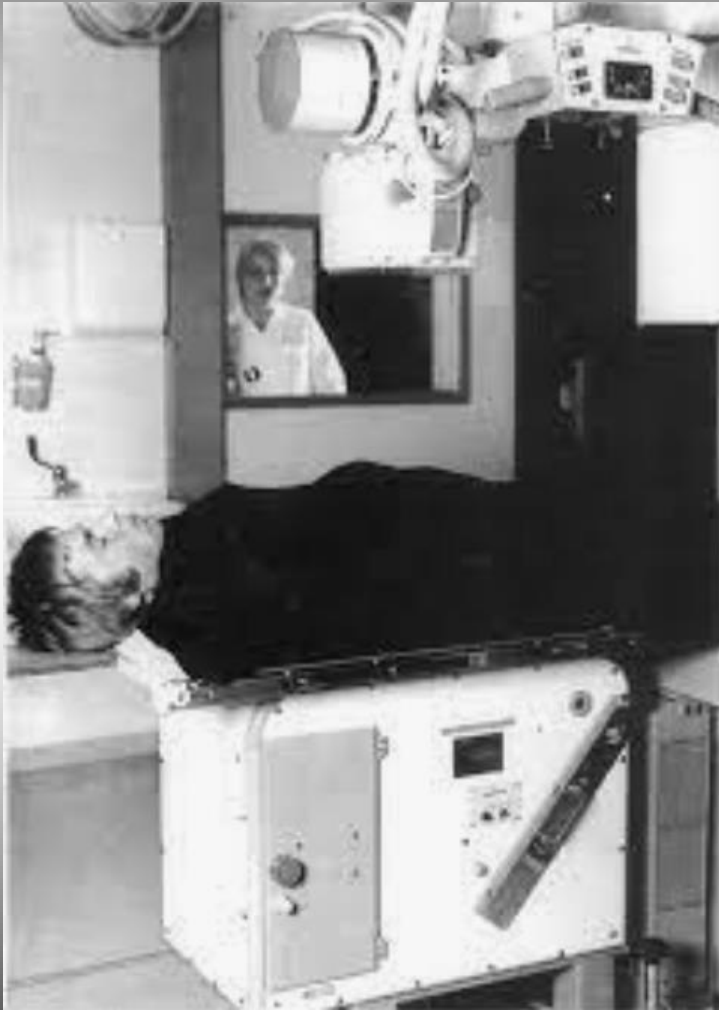


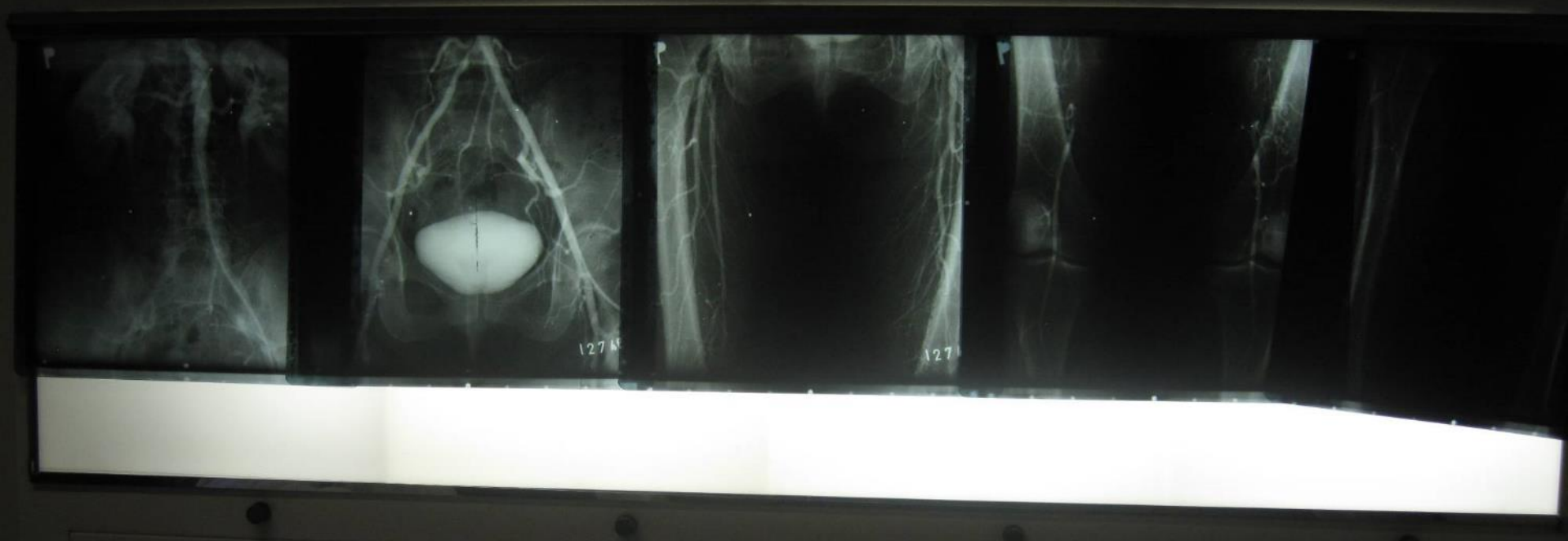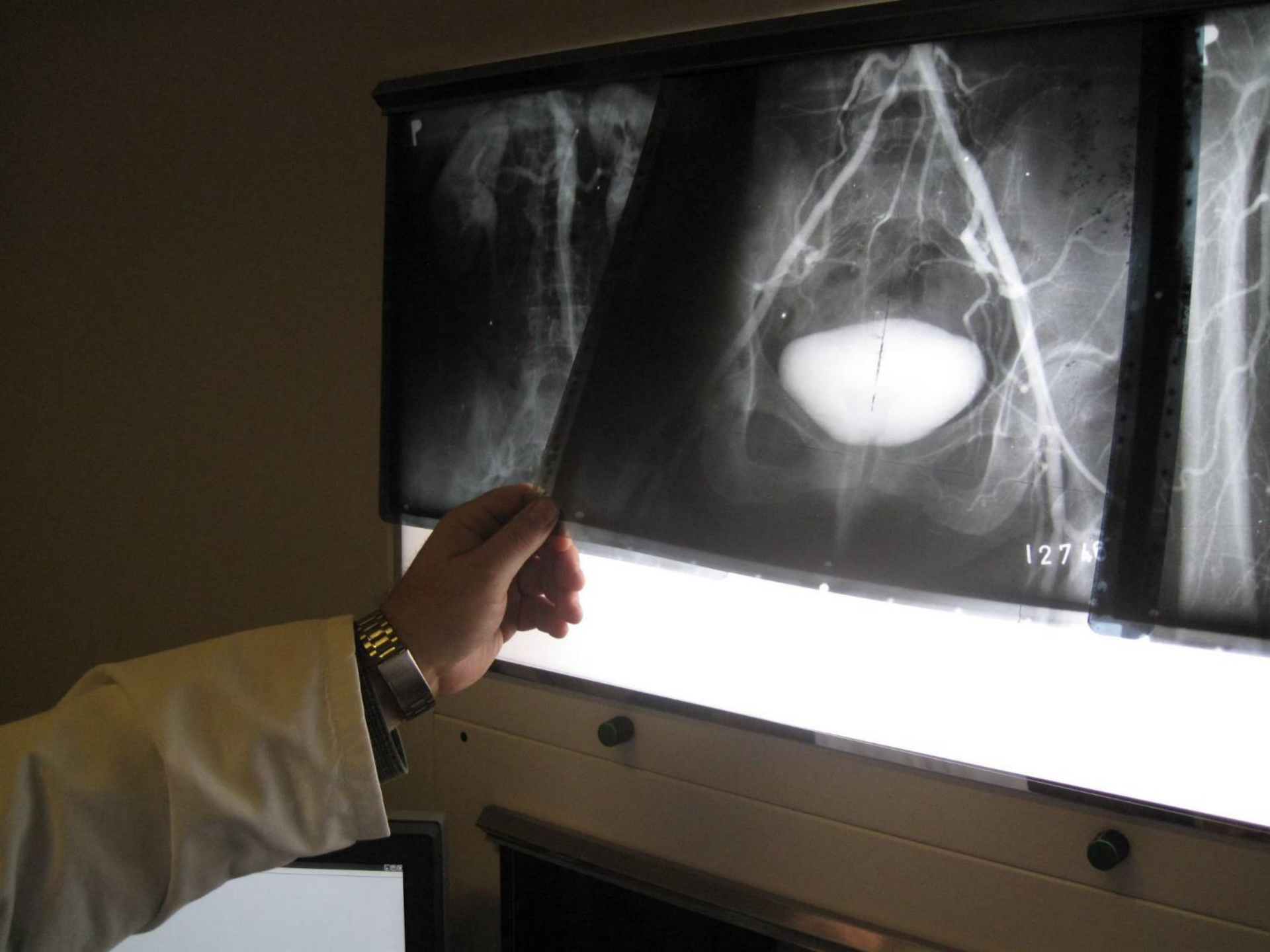


# 1970

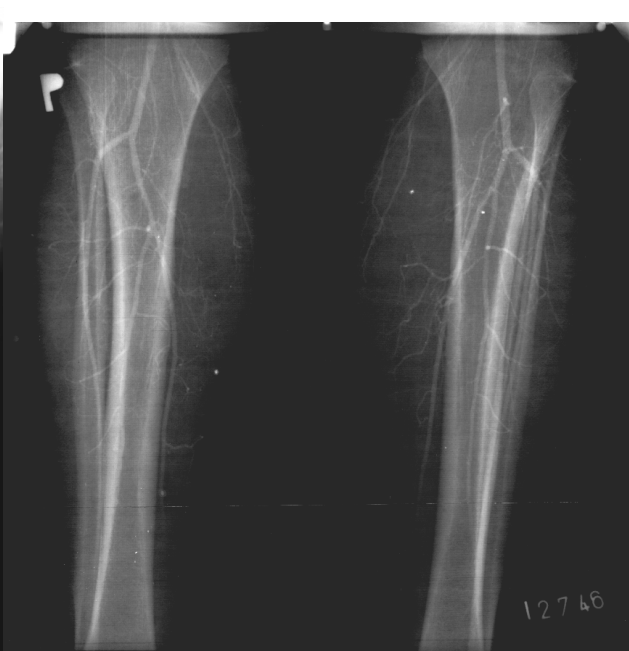
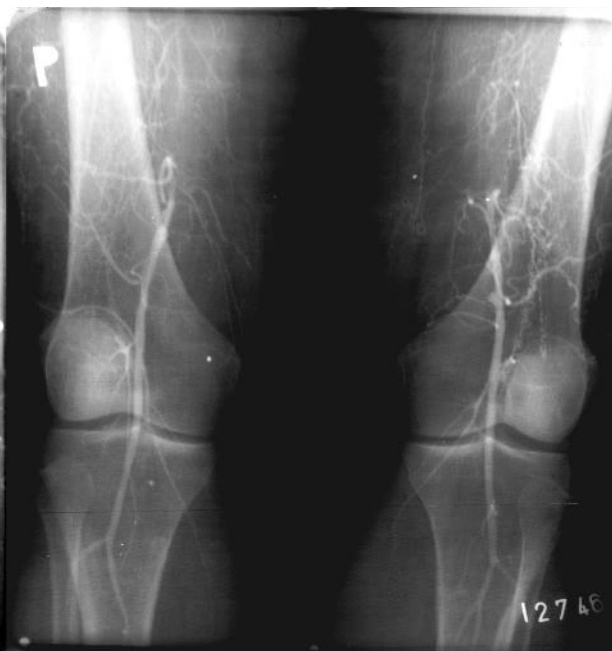
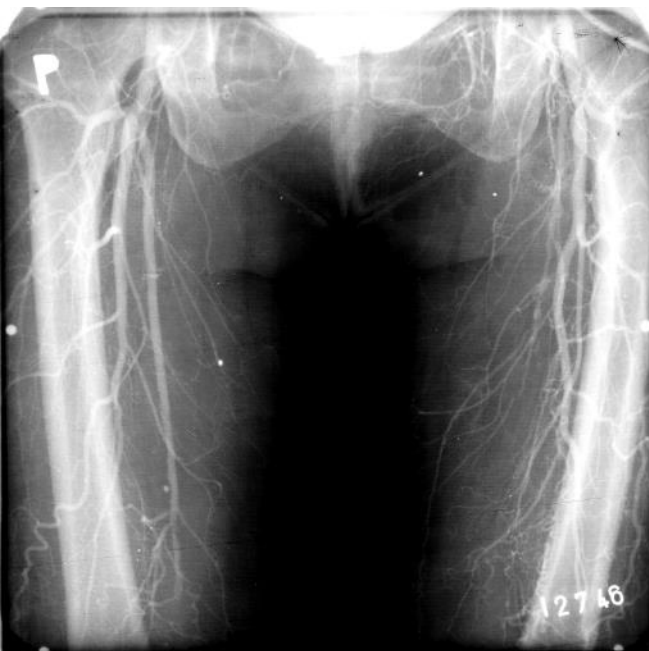
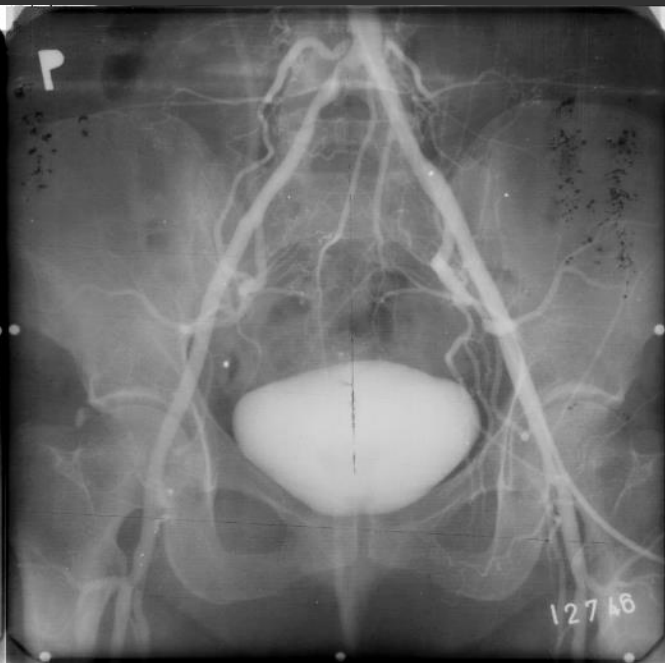
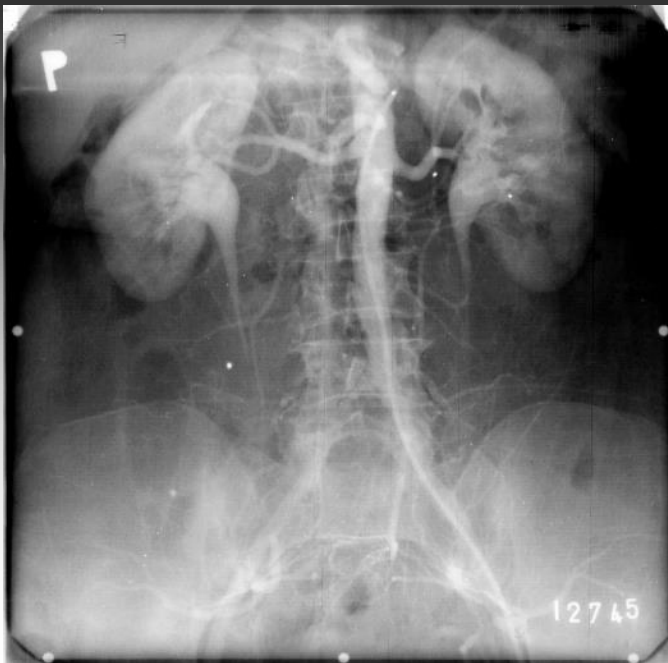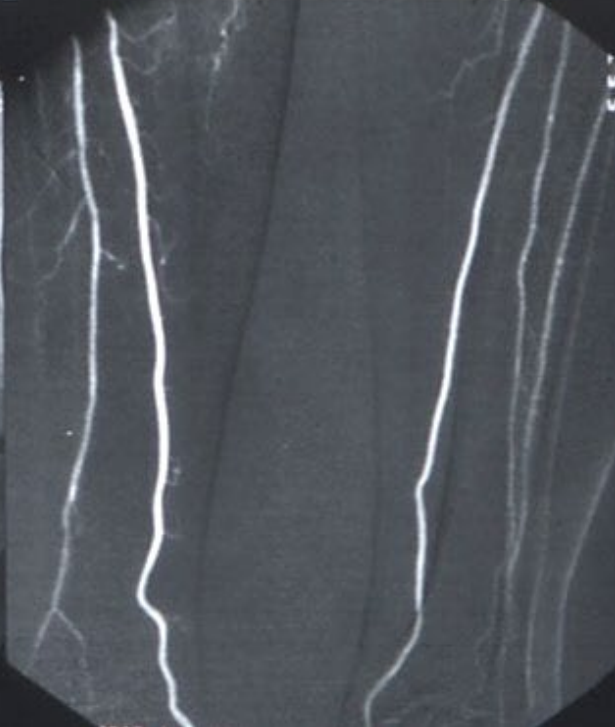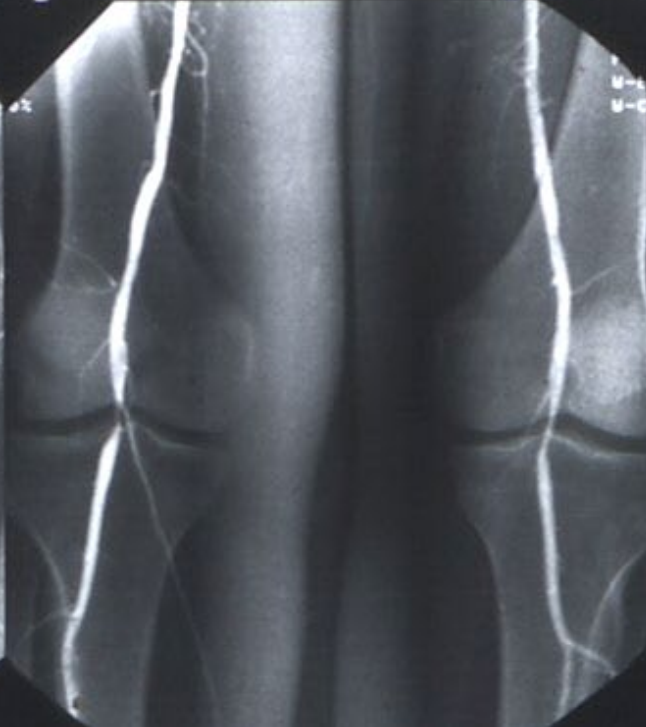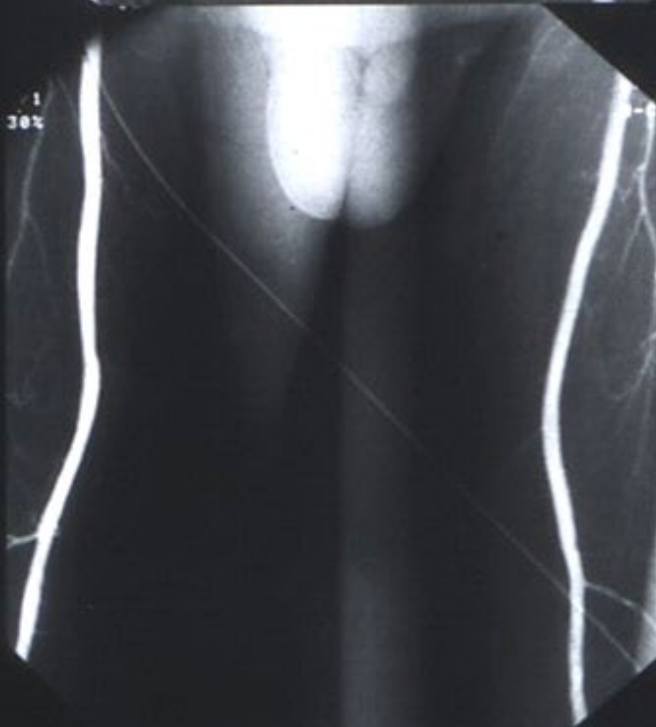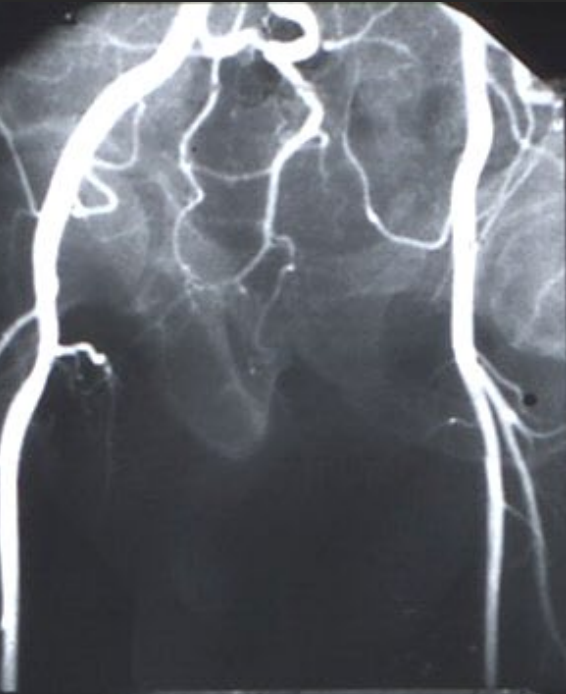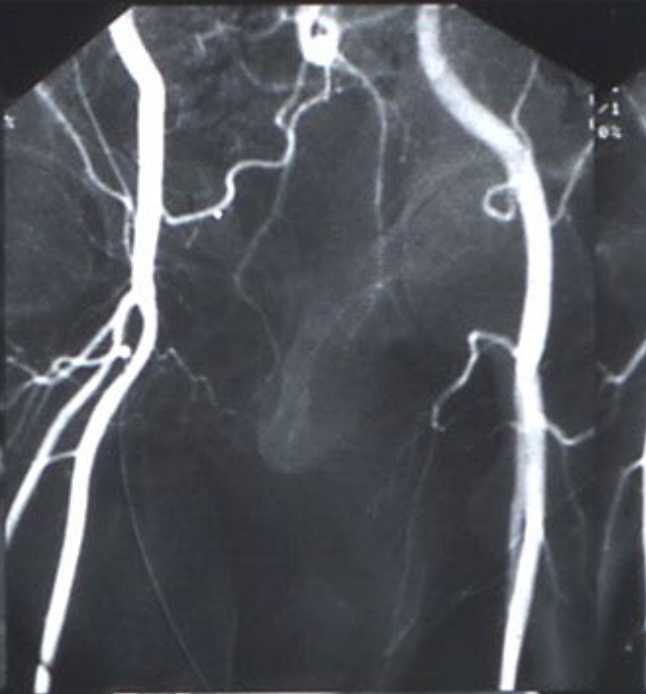
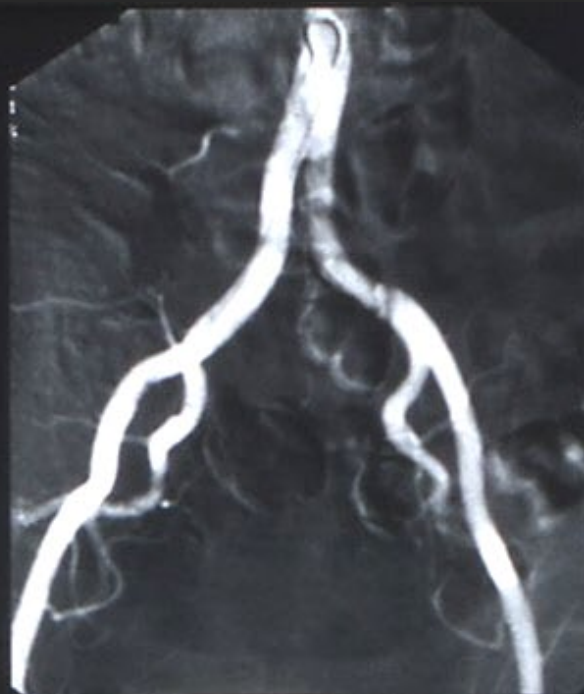




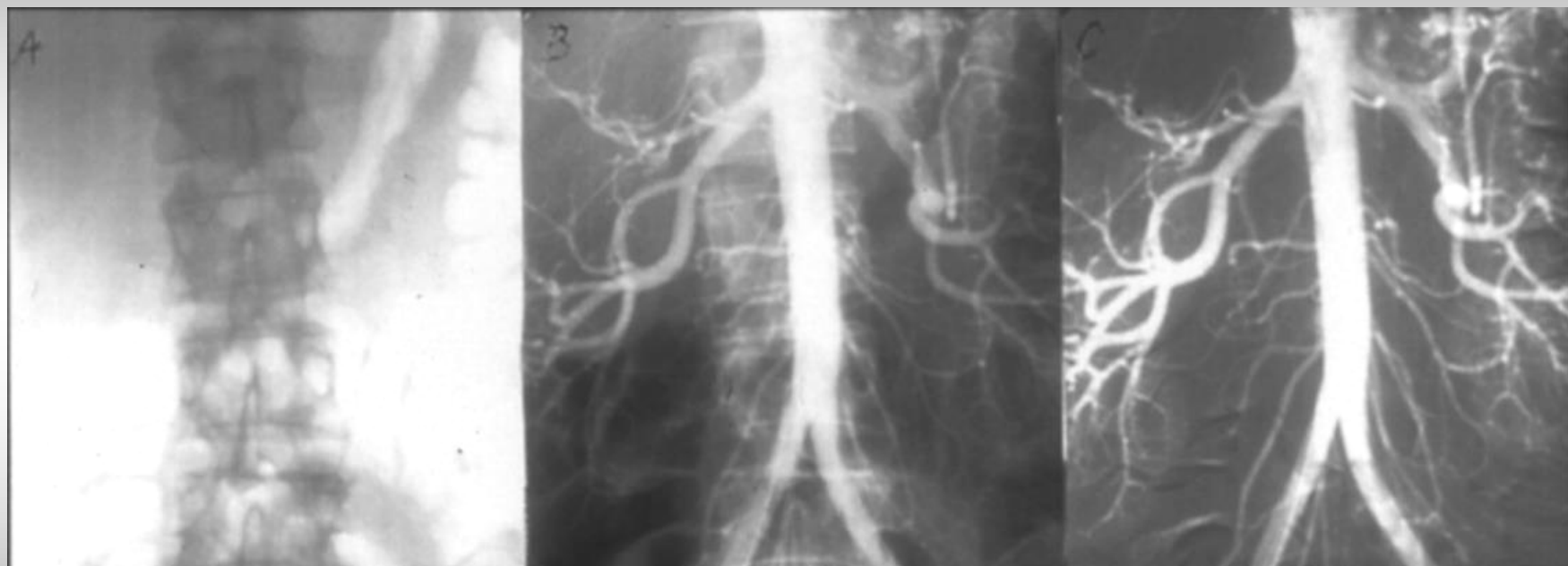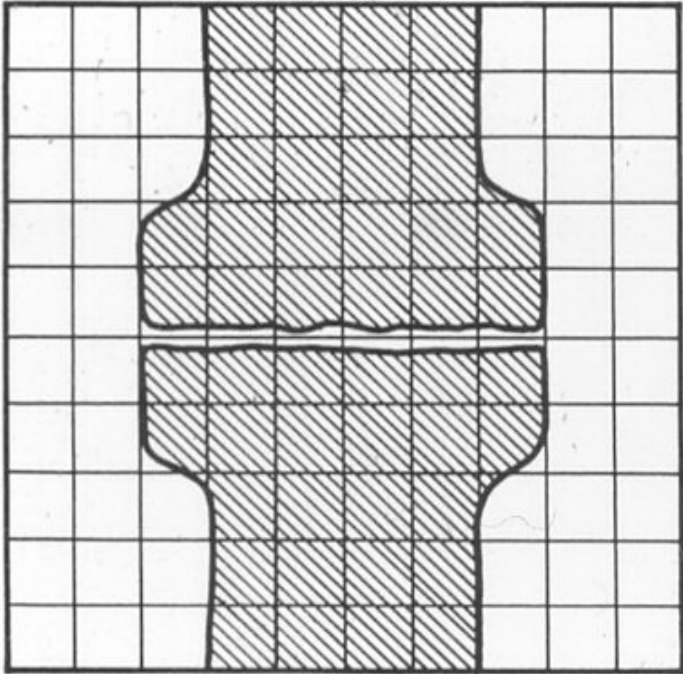
127 18



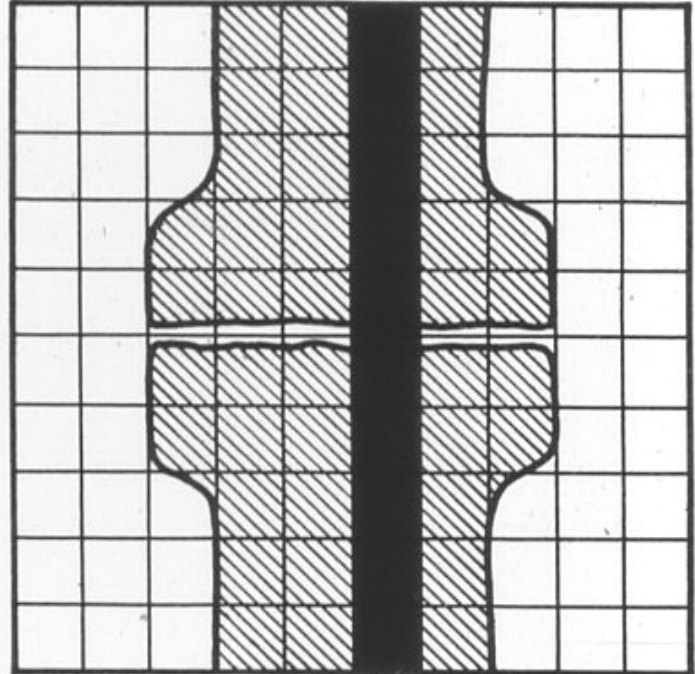








□ 0    ▨ 1    ■ 2



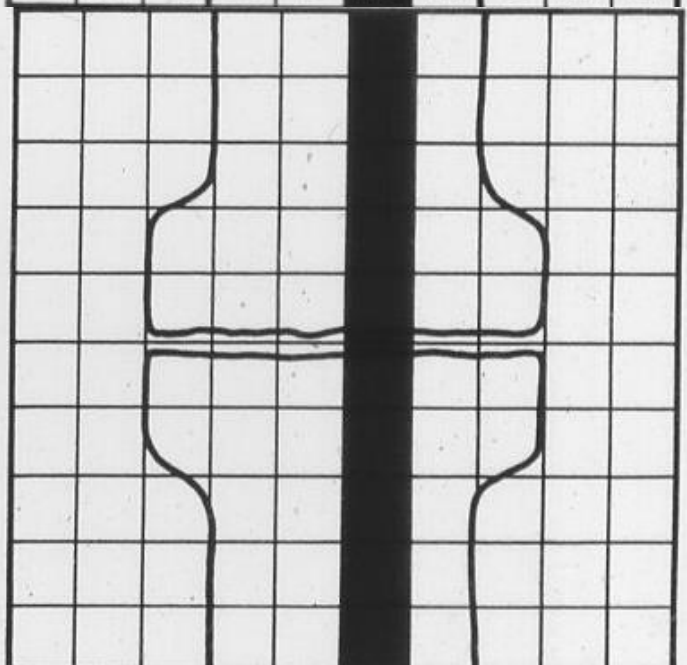

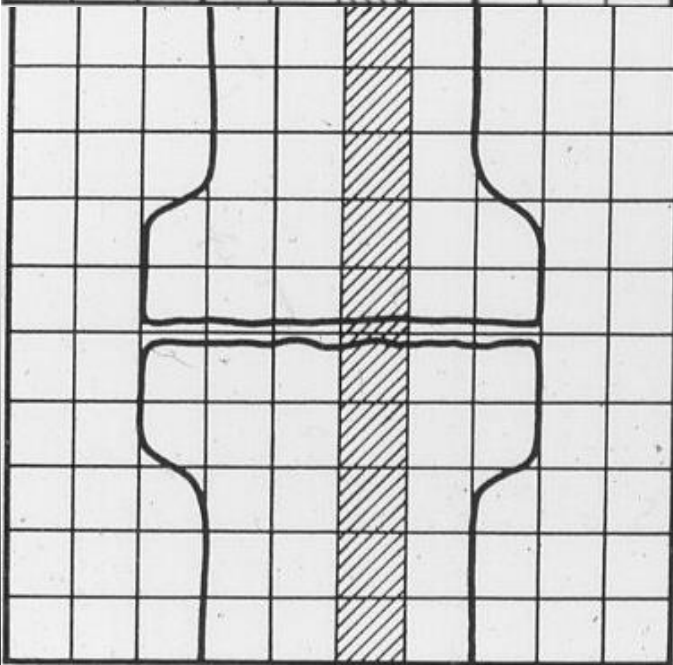

□ 0    ▨ 1    ■ 2

0	0	0	1	1	1	1	0	0	0
0	0	0	1	1	1	1	0	0	0
0	0	0	1	1	1	1	0	0	0
0	0	1	1	1	1	1	1	0	0
0	0	1	1	1	1	1	1	0	0
0	0	1	1	1	1	1	1	0	0
0	0	1	1	1	1	1	1	0	0
0	0	1	1	1	1	1	1	0	0
0	0	0	1	1	1	1	0	0	0
0	0	0	1	1	1	1	0	0	0
0	0	0	1	1	1	1	0	0	0

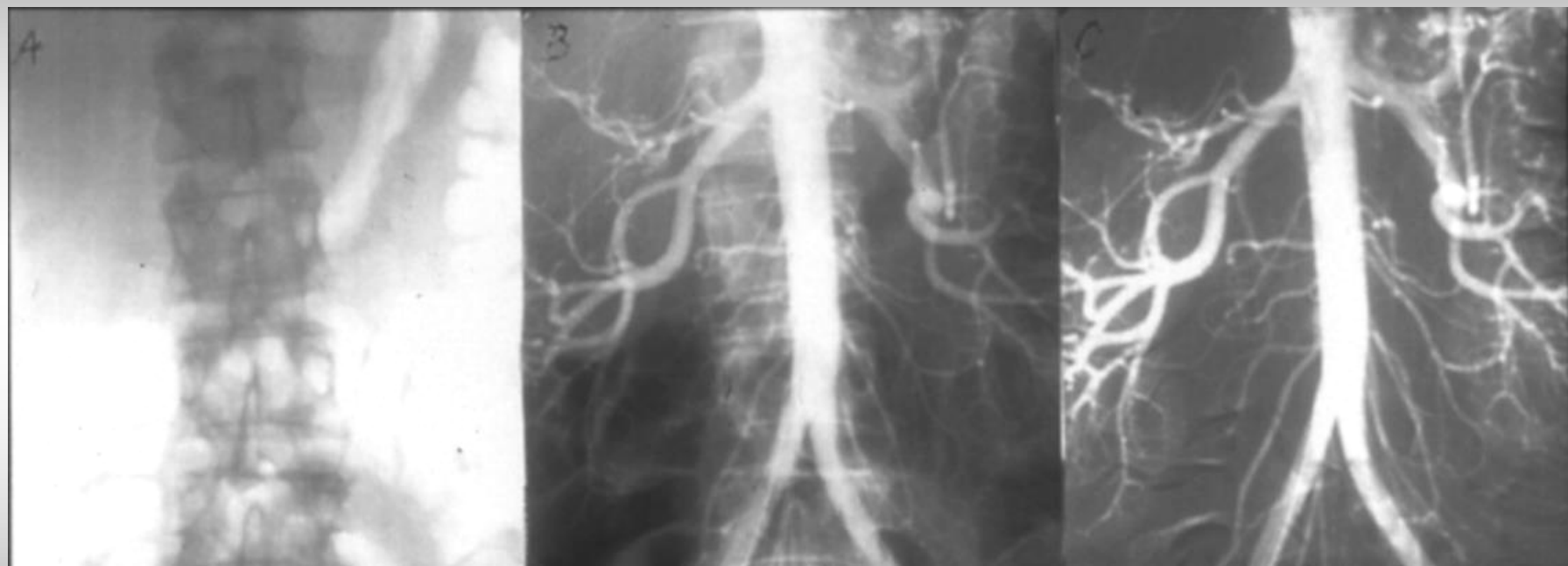0	0	0	1	1	2	1	0	0	0
0	0	0	1	1	2	1	0	0	0
0	0	0	1	1	2	1	0	0	0
0	0	1	1	1	2	1	1	0	0
0	0	1	1	1	2	1	1	0	0
0	0	1	1	1	2	1	1	0	0
0	0	1	1	1	2	1	1	0	0
0	0	0	1	1	2	1	0	0	0
0	0	0	1	1	2	1	0	0	0
0	0	0	1	1	2	1	0	0	0
0	0	0	1	1	2	1	0	0	0

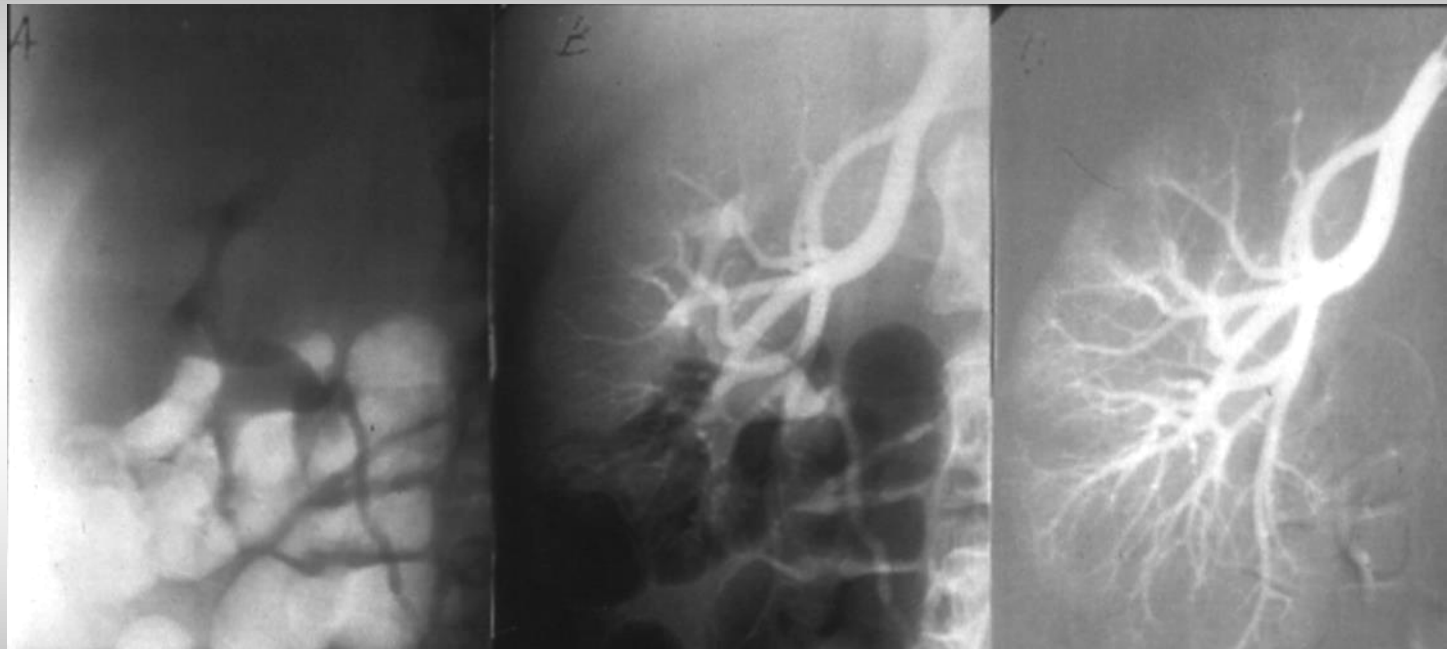














# *Historie angiografie a PTA*

- 1953 Seldinger: Perkutánní zavedení katétru do tepny punkční technikou
- 1964 Dotter: Transluminální angioplastika koaxiální cévkou
- 1974 Grüntzig: Transluminální angioplastika balónkovou cévkou
- 1980→ Stenty, mechanická rekanalizační zařízení, stentgrafty, TIPS


# Cardiac catheterization and angiographic techniques of Future

June 1963, Karlovy Vary






“A cardiac catheter can be more than a tool for passive means for diagnostic observation; used with imagination it can become an important surgical instrument”.

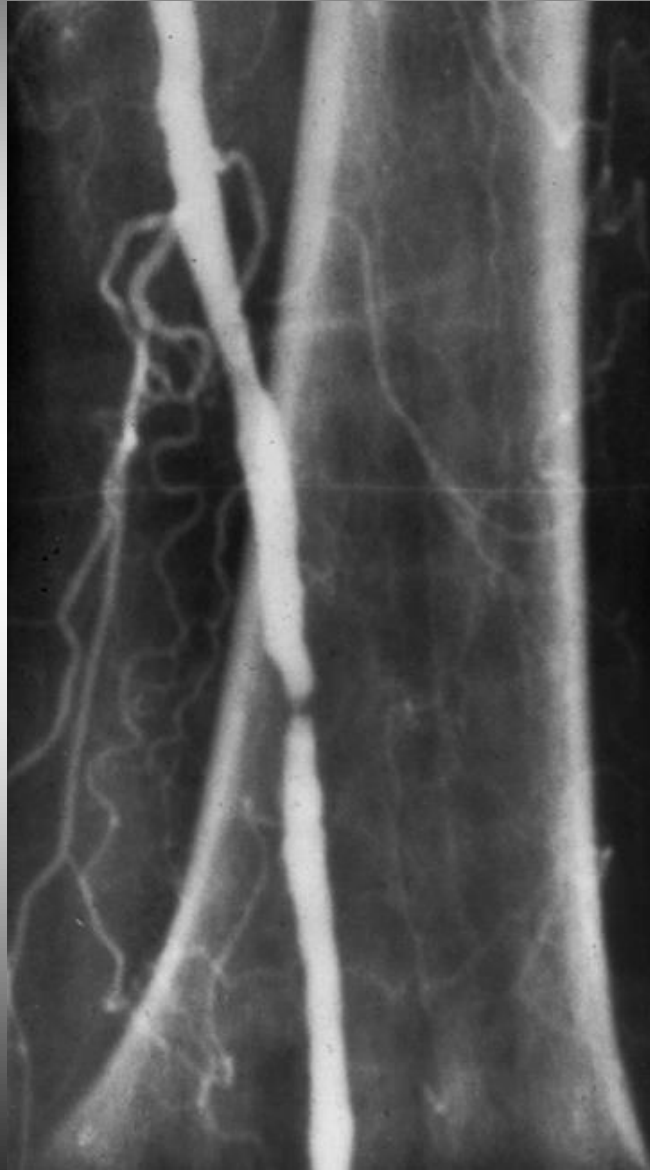
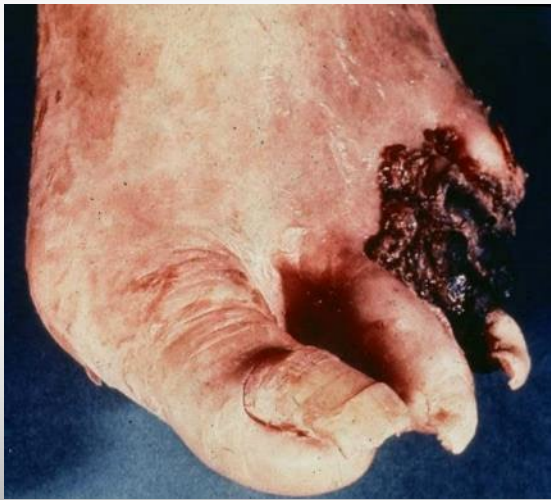

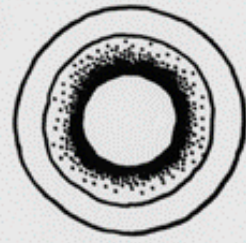

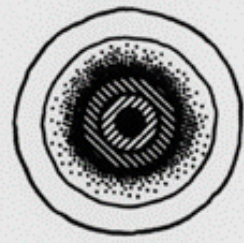
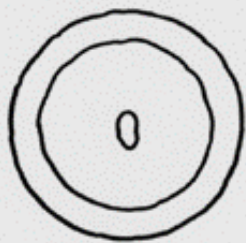




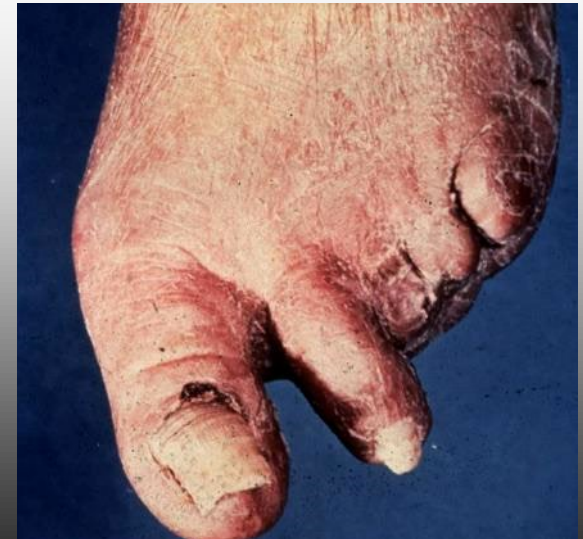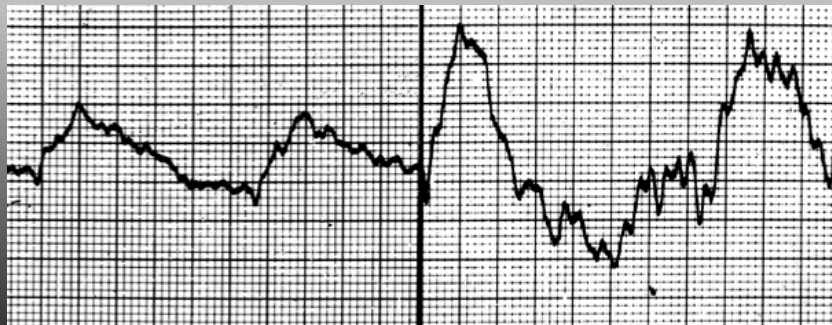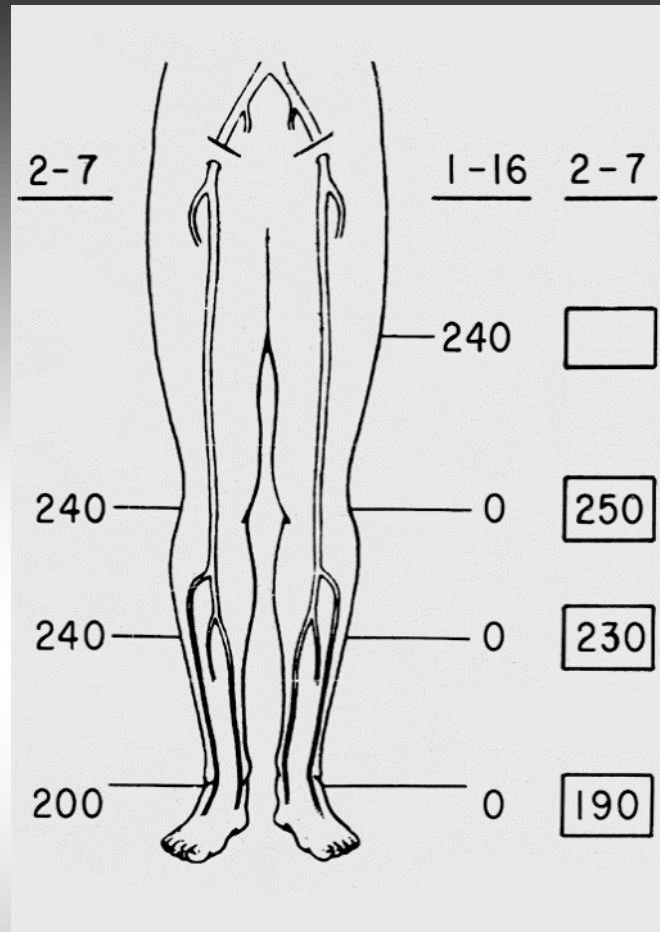
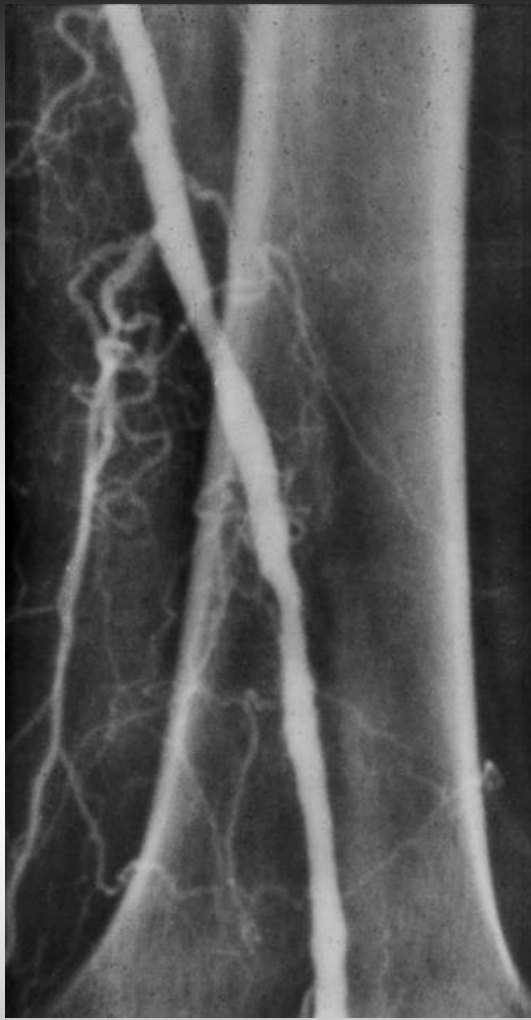*Josef Rösch*

*January 16, 1964*











# *Historie angiografie a PTA*

- 1953 Seldinger: Perkutánní zavedení katétru do tepny punkční technikou
- 1964 Dotter: Transluminální angioplastika koaxiální cévkou
- 1974 Grüntzig: Transluminální angioplastika balónkovou cévkou
- 1980→ Stenty, mechanická rekanalizační zařízení, stentgrafty, TIPS

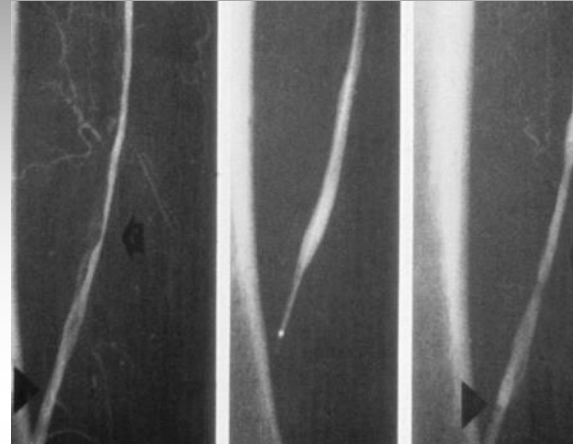
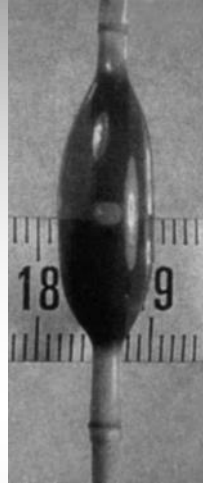



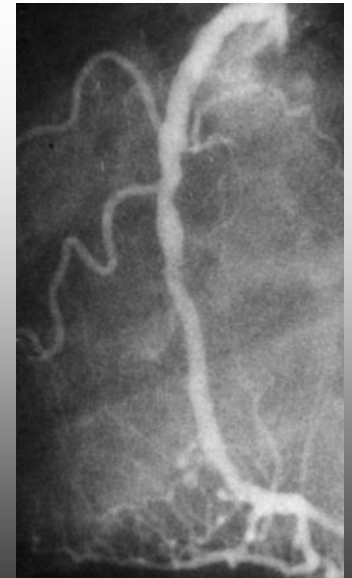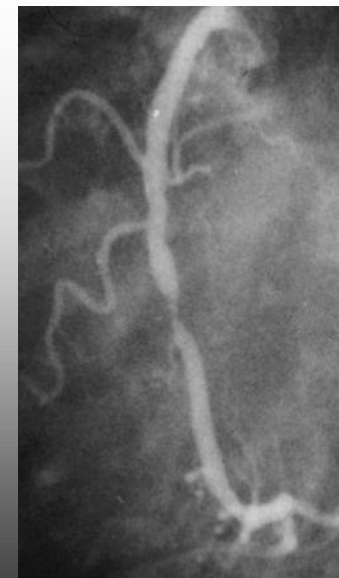# *Balónková angioplastika*

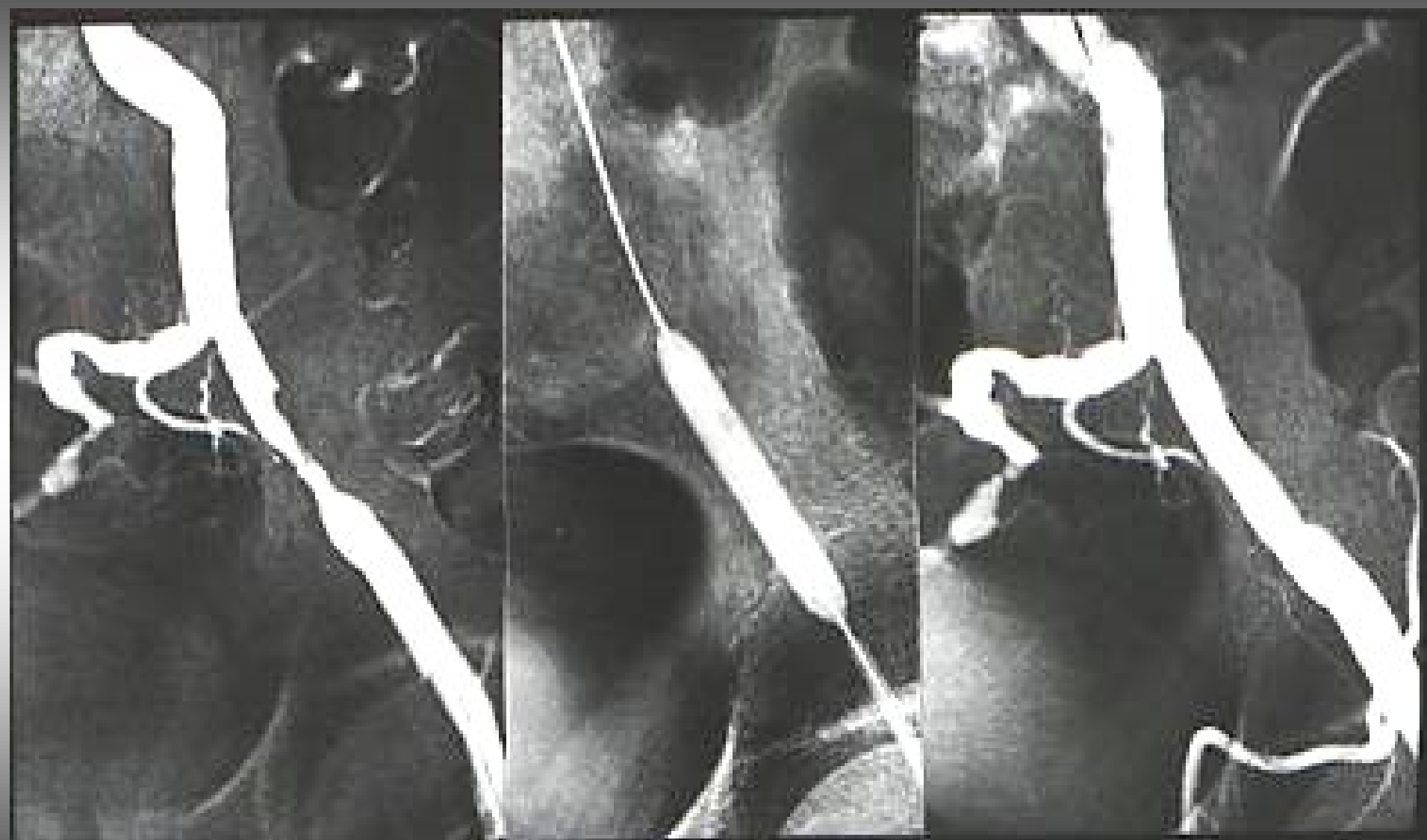


A. Grüntzig



1975

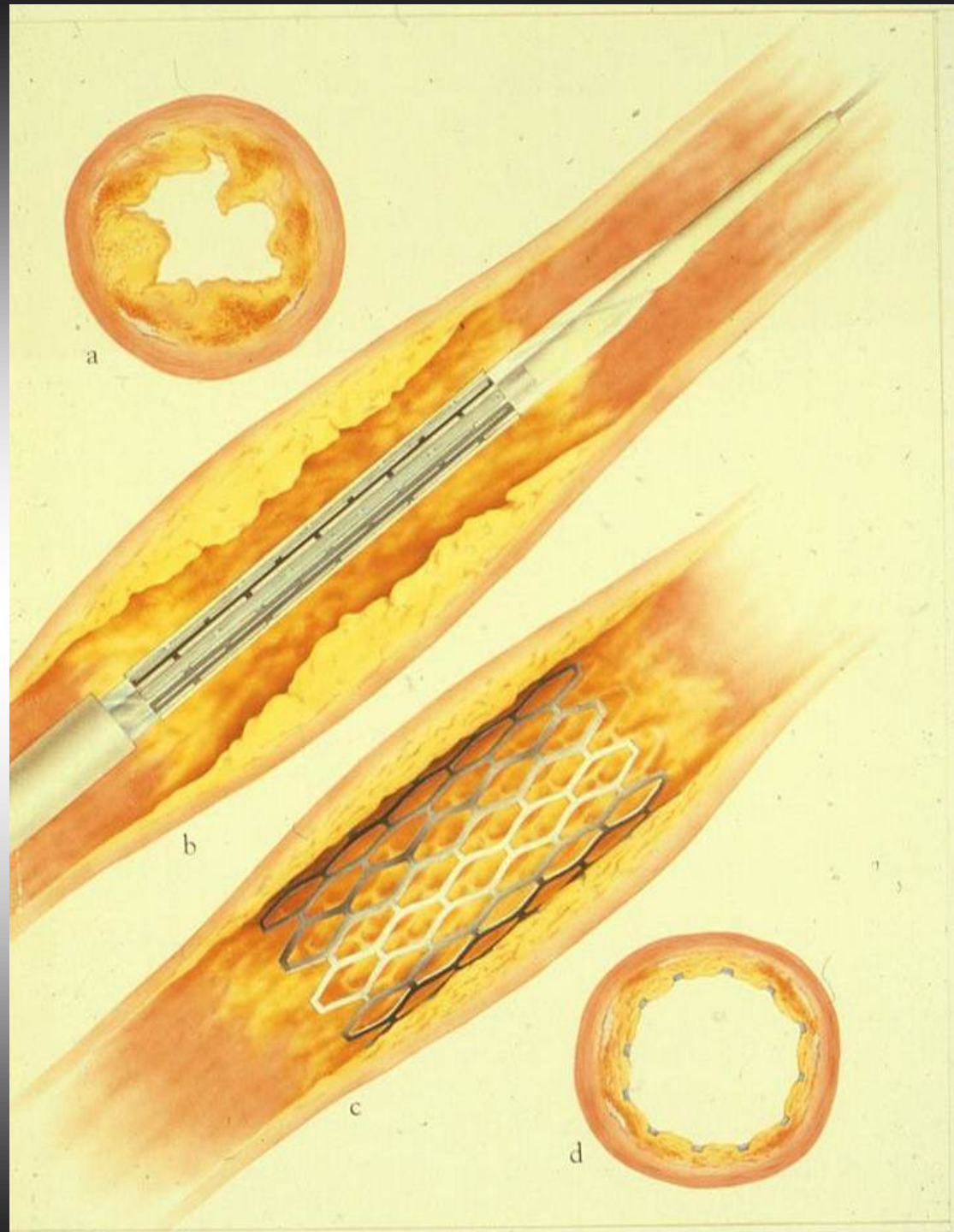




# *Historie angiografie a PTA*

- 1953 Seldinger: Perkutánní zavedení katétru do tepny punkční technikou
- 1964 Dotter: Transluminální angioplastika koaxiální cévkou
- 1974 Grüntzig: Transluminální angioplastika balónkovou cévkou
- 1980 → Stenty, mechanická rekanalizační zařízení, stentgrafty, TIPS

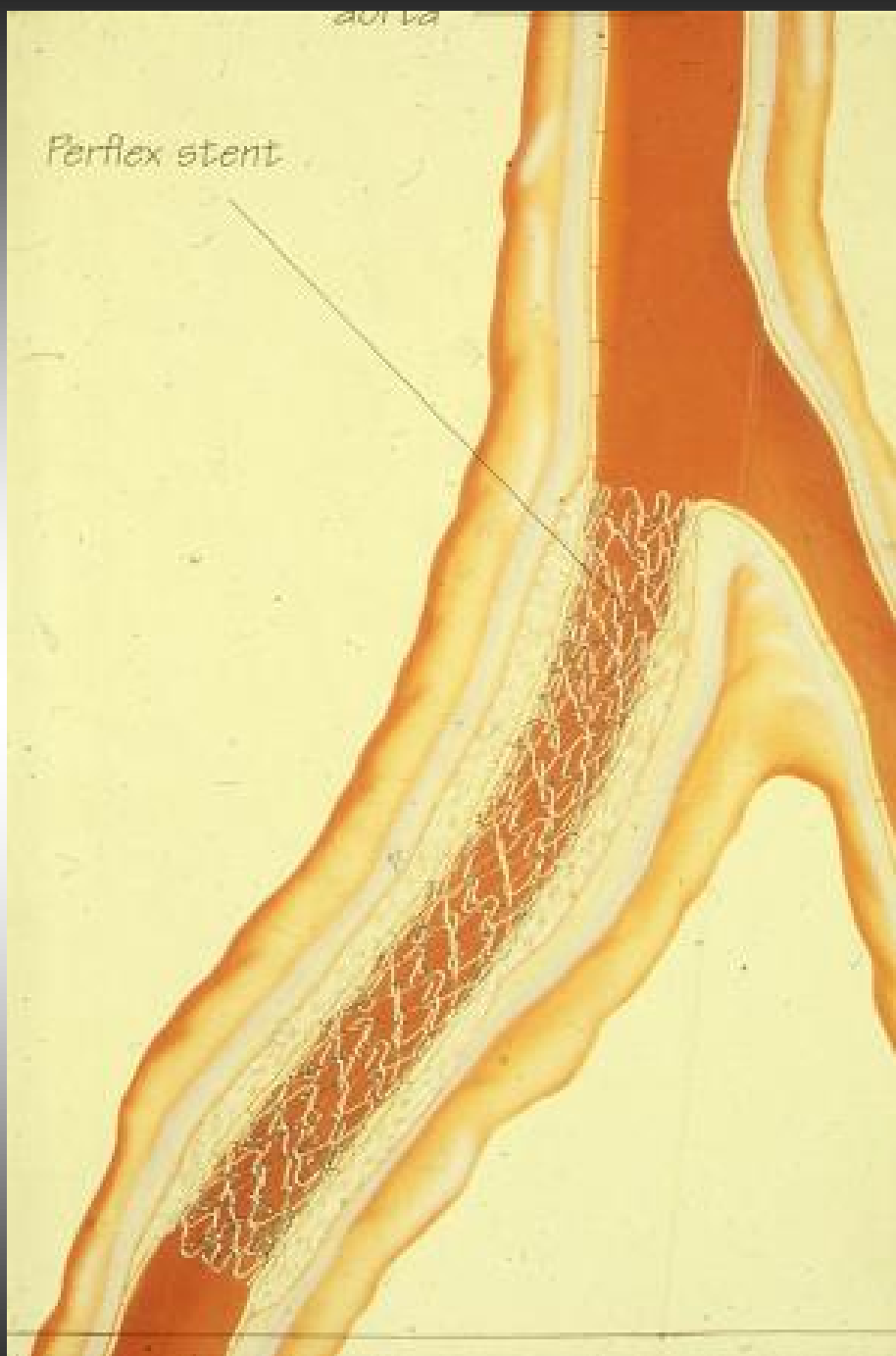


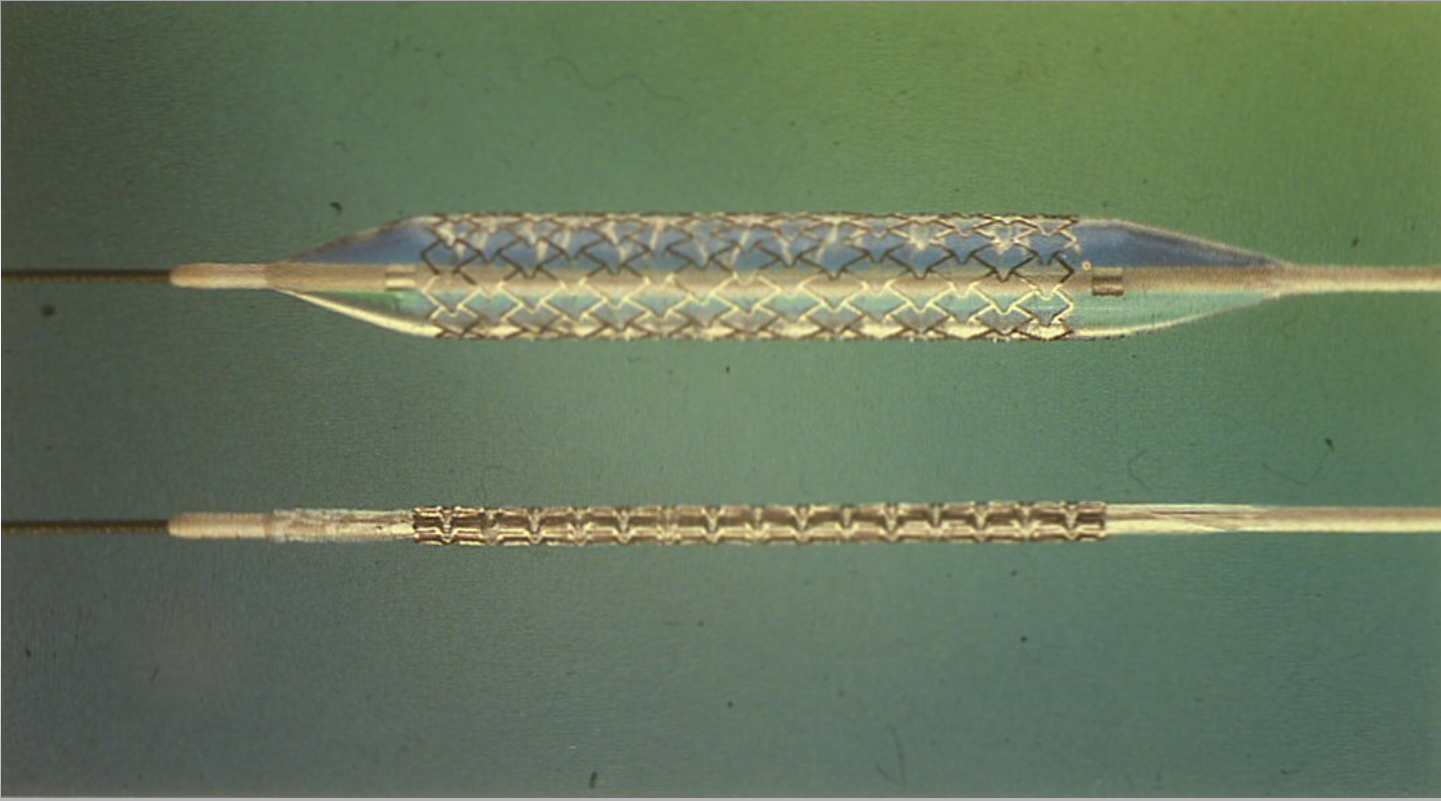


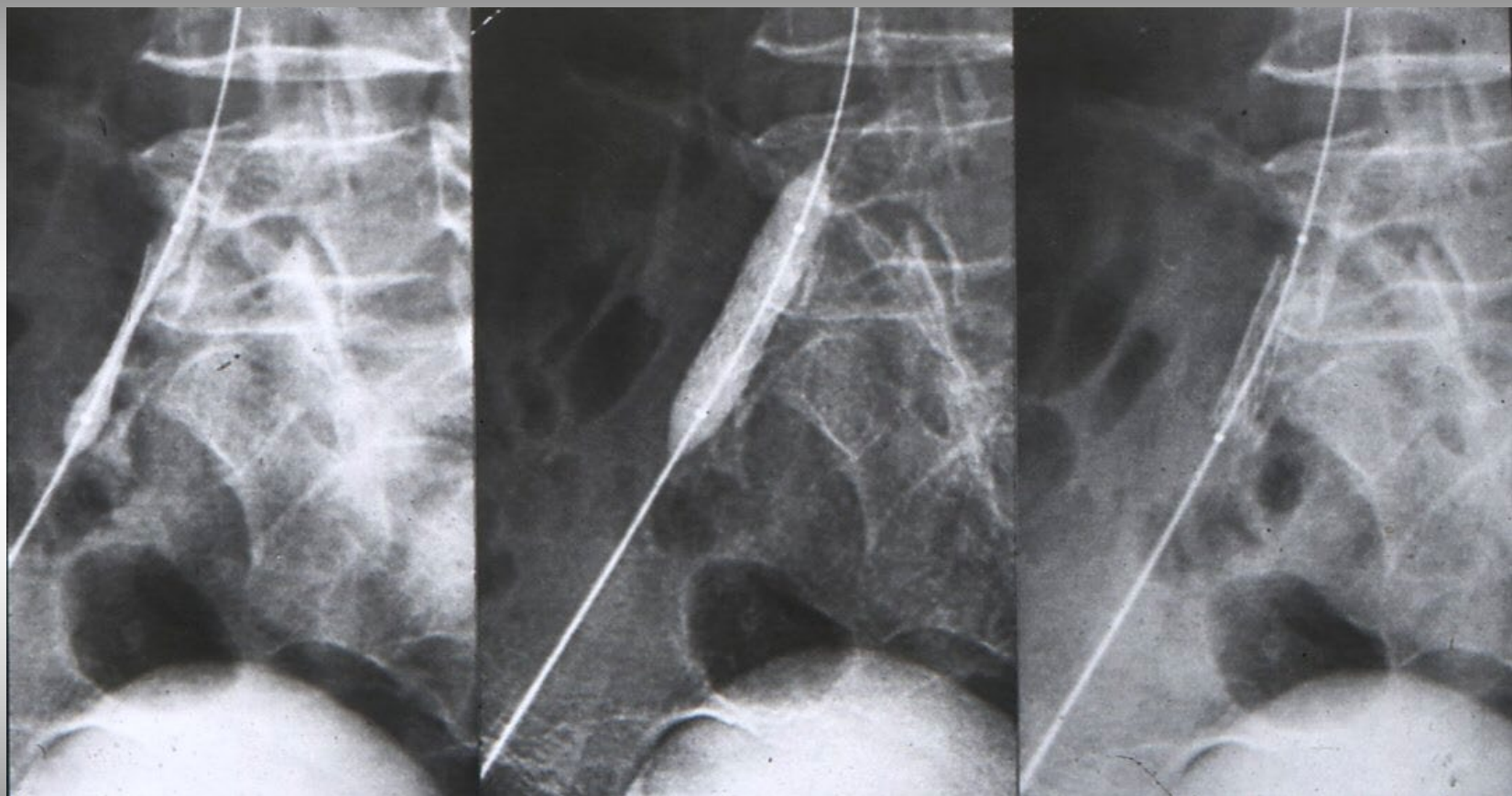


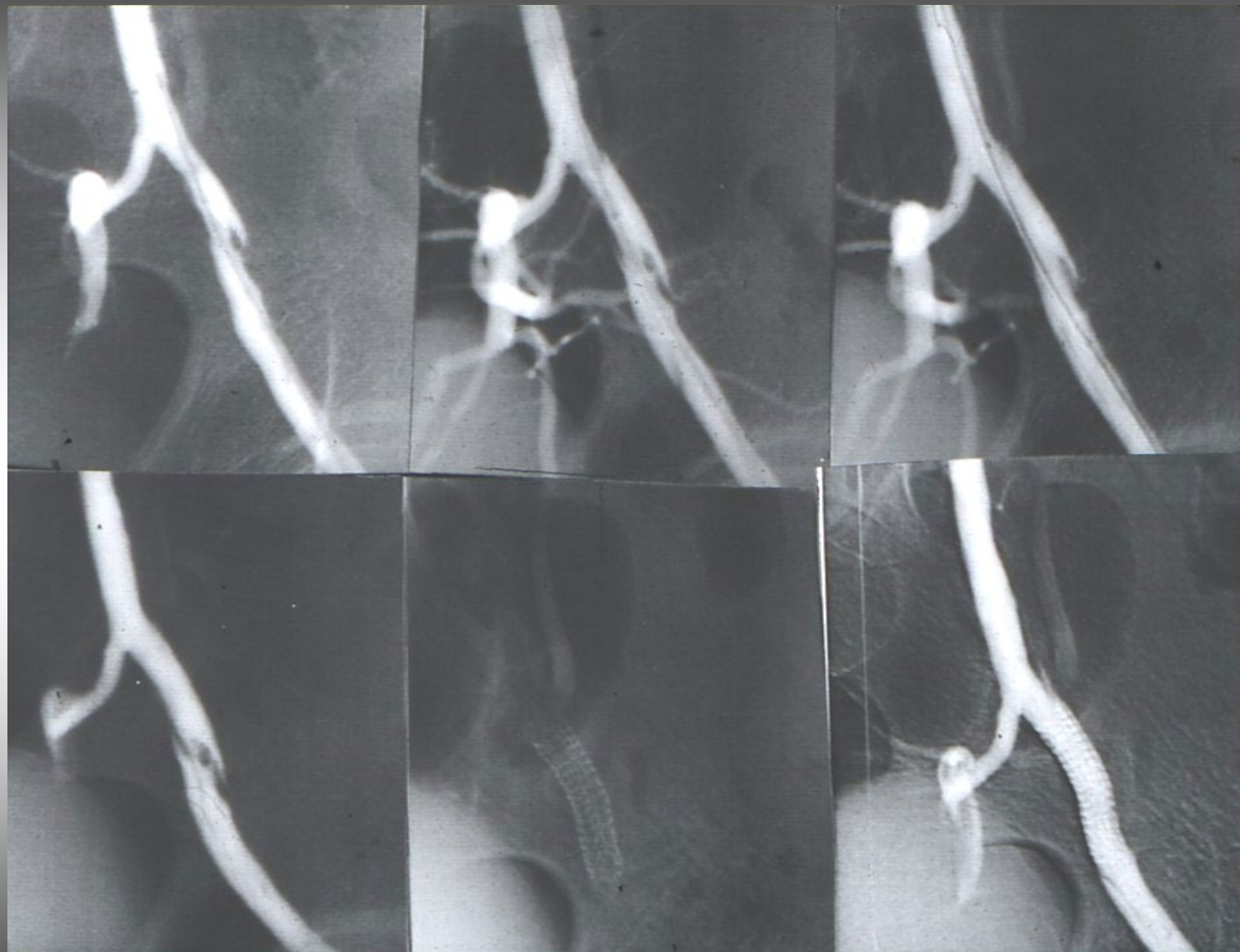
aorta

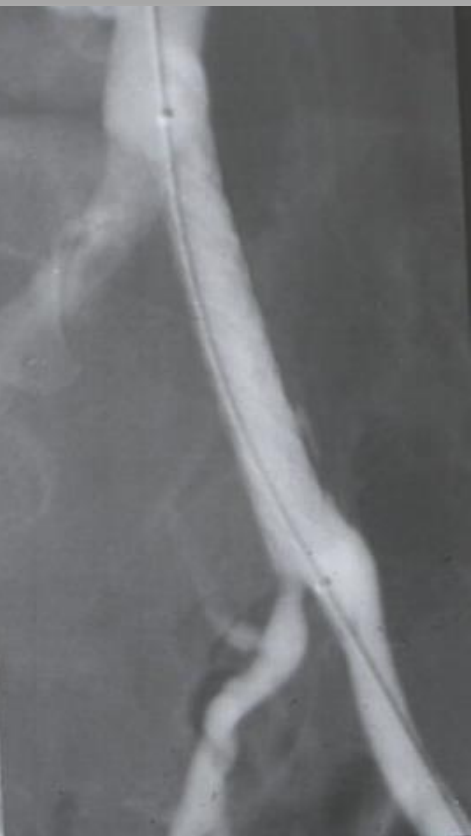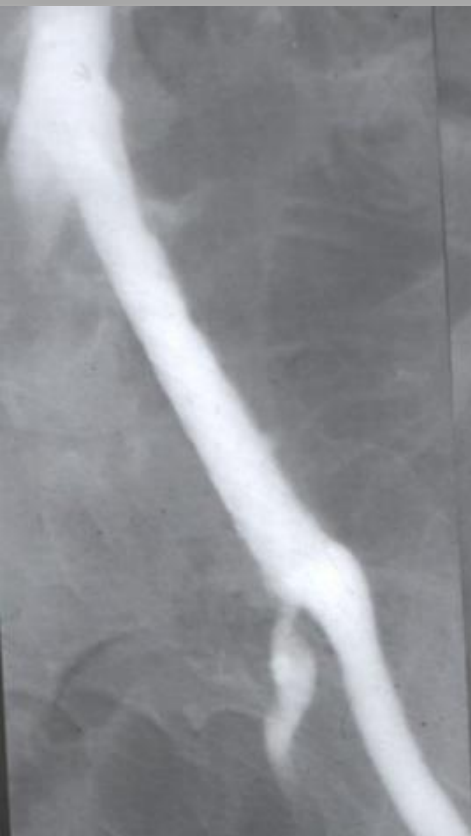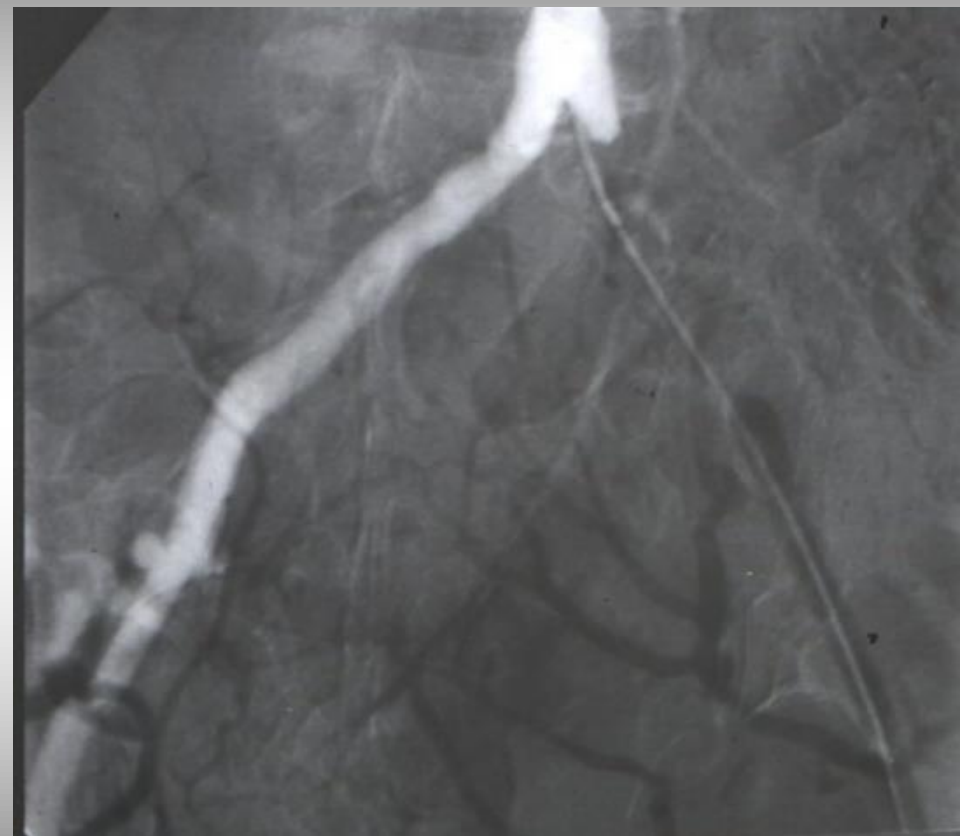
Perflex stent



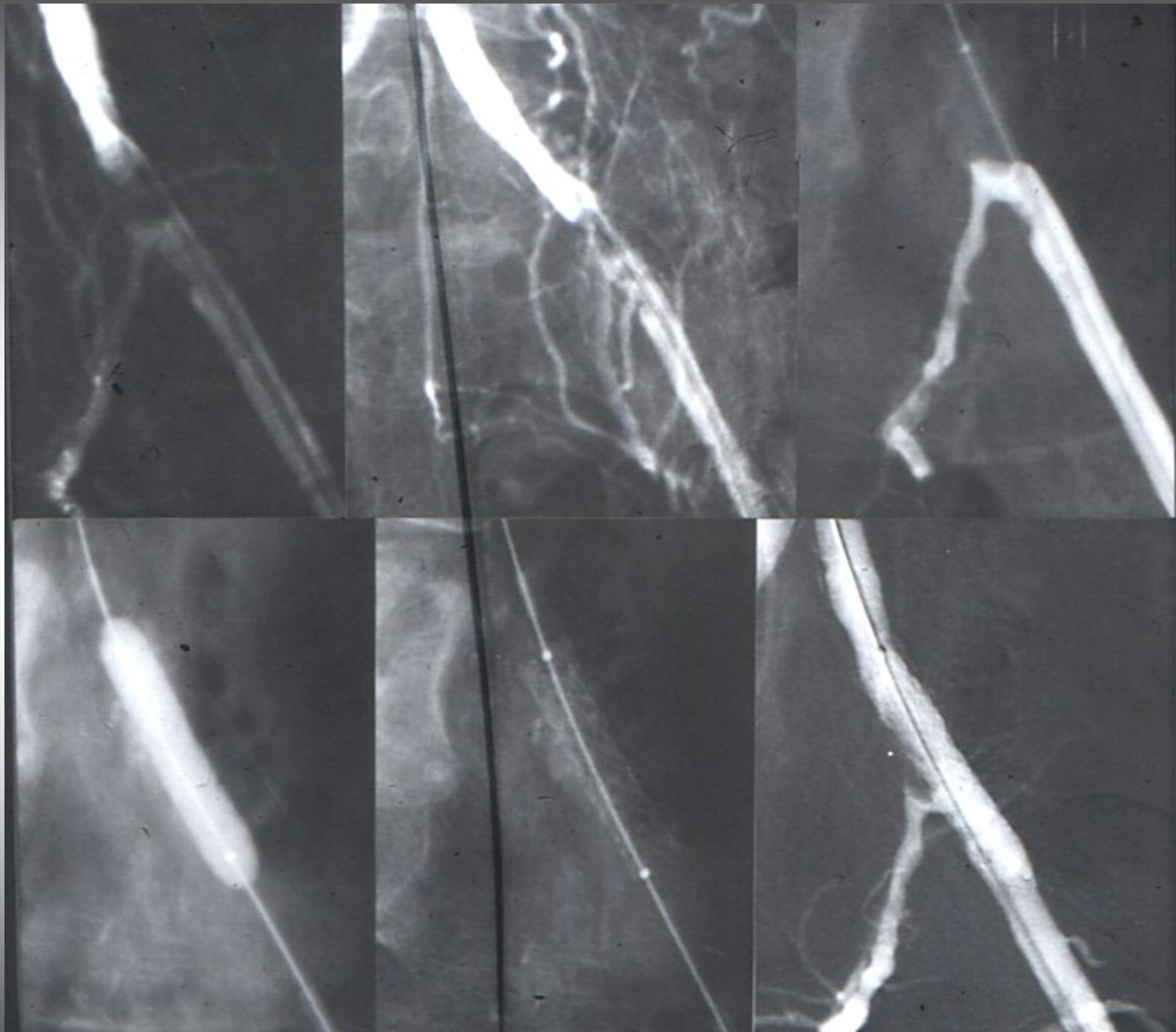


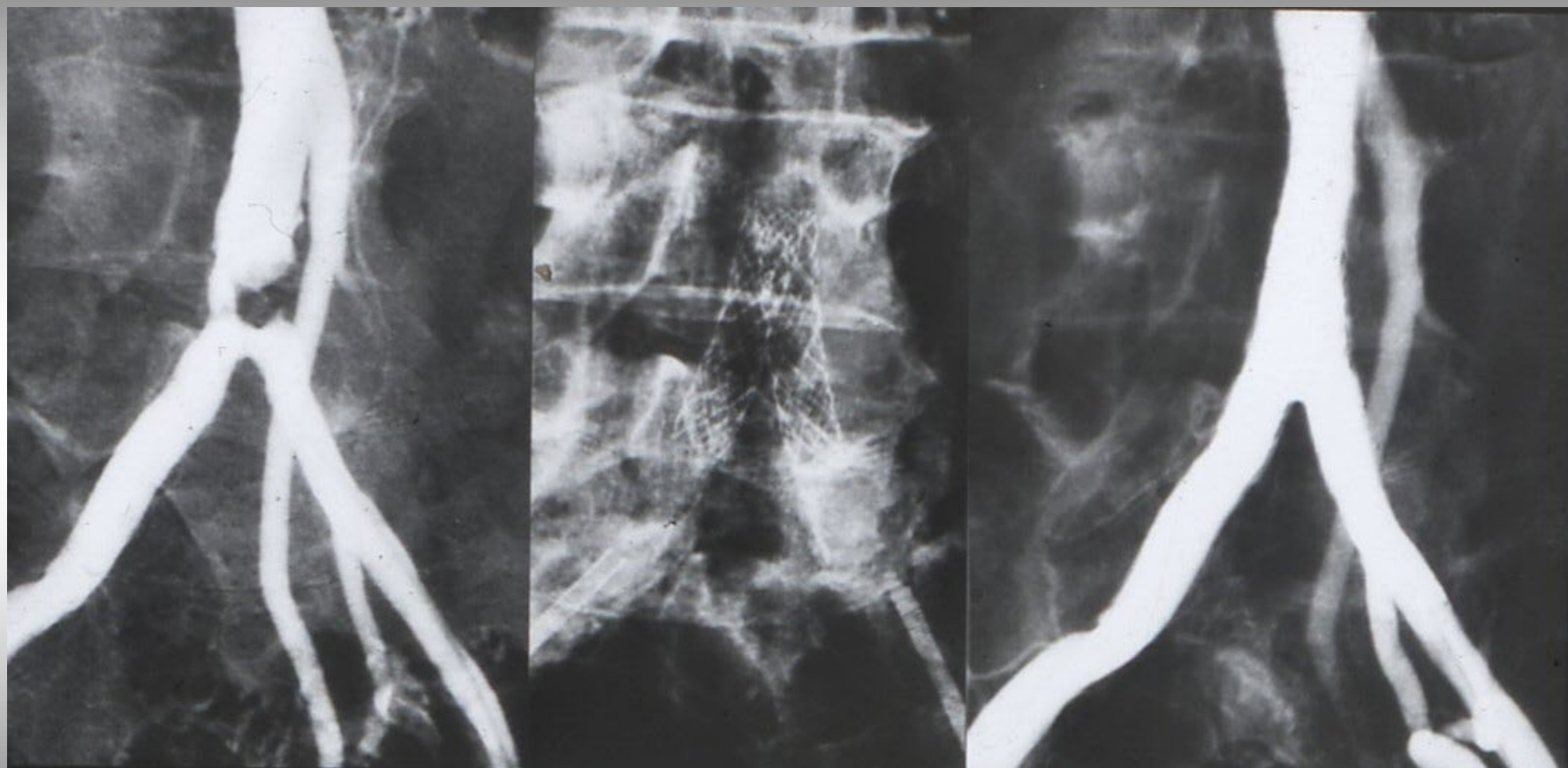


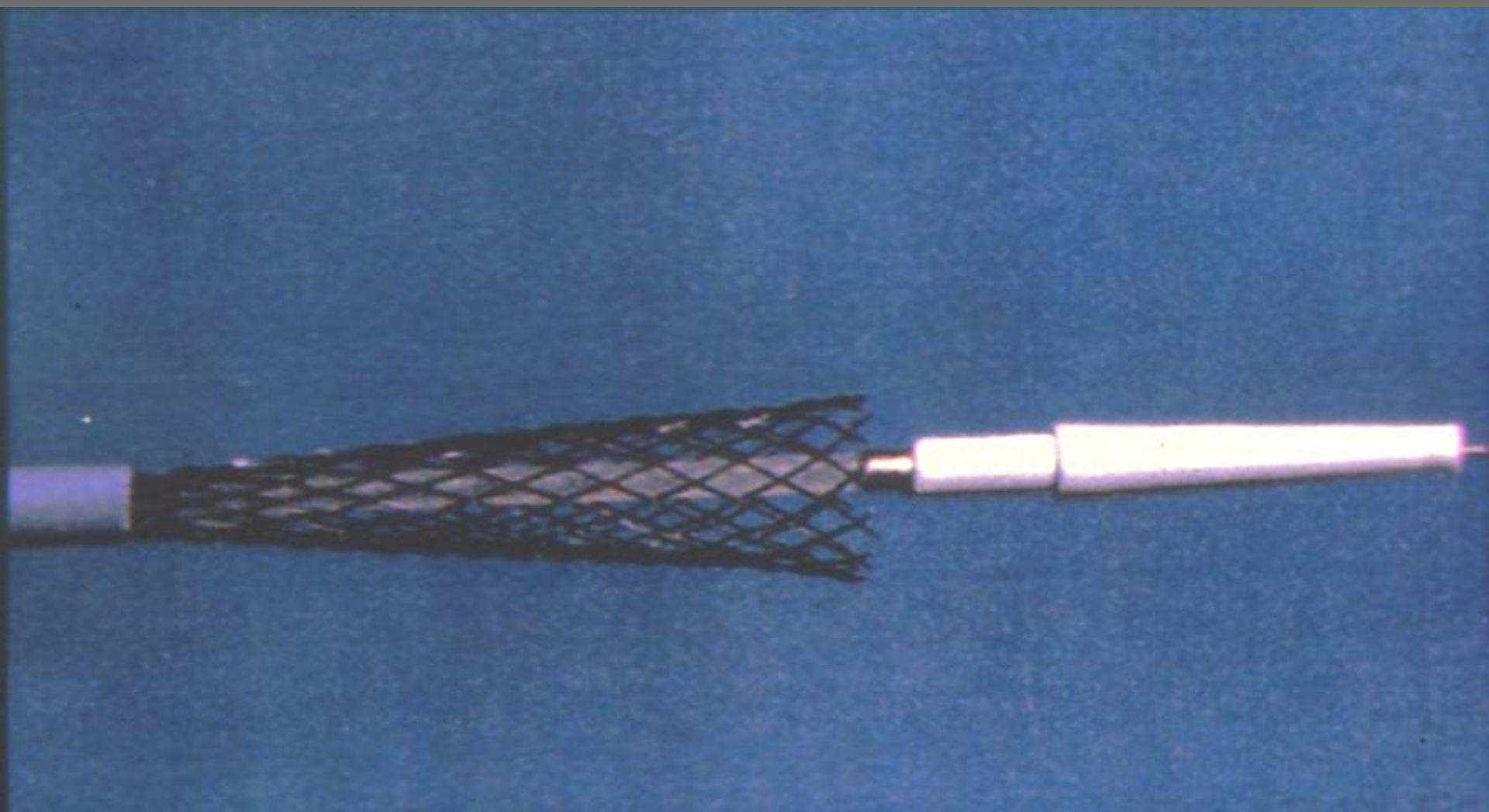


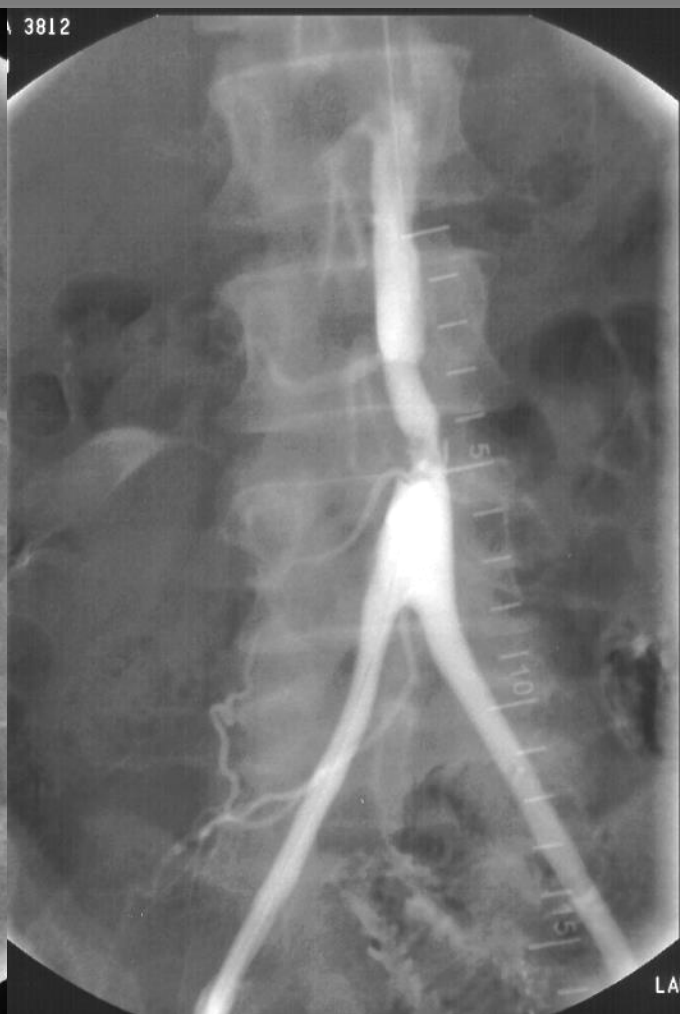
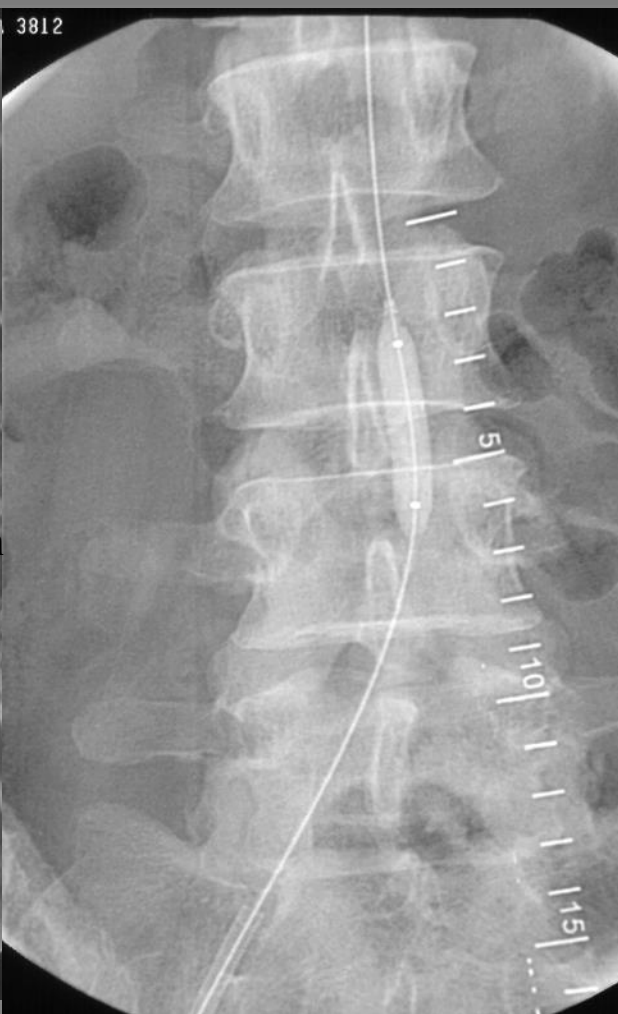
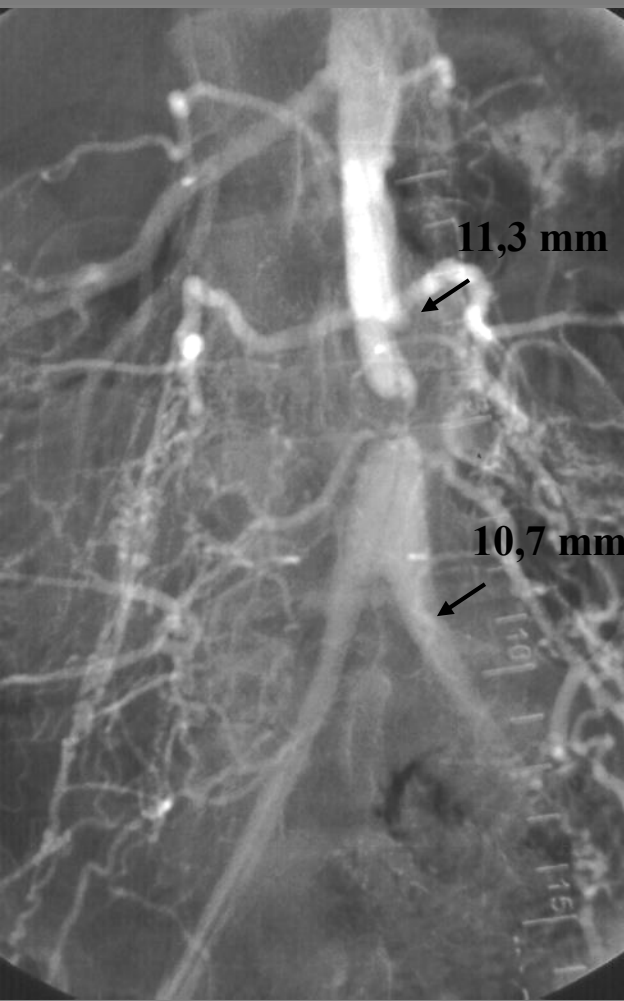




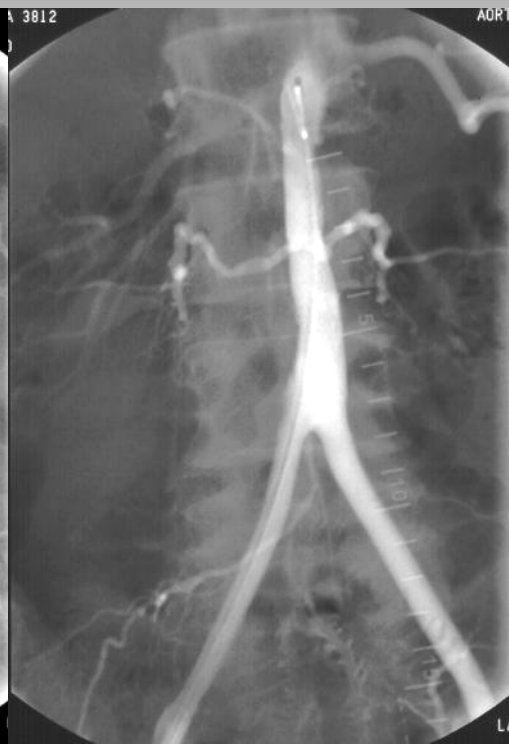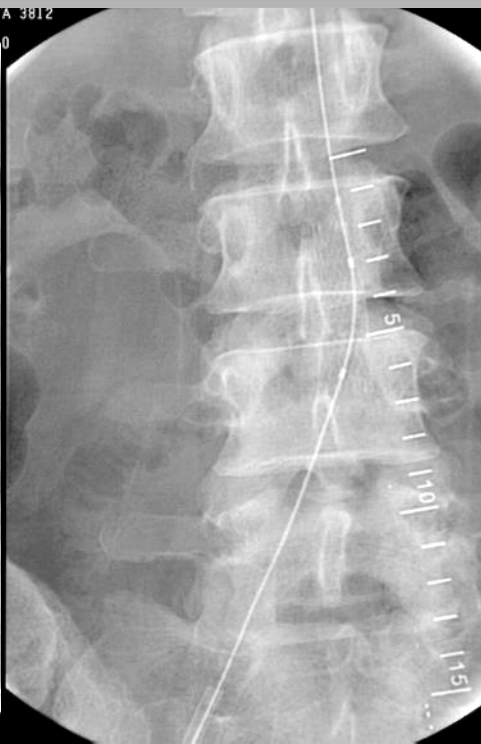
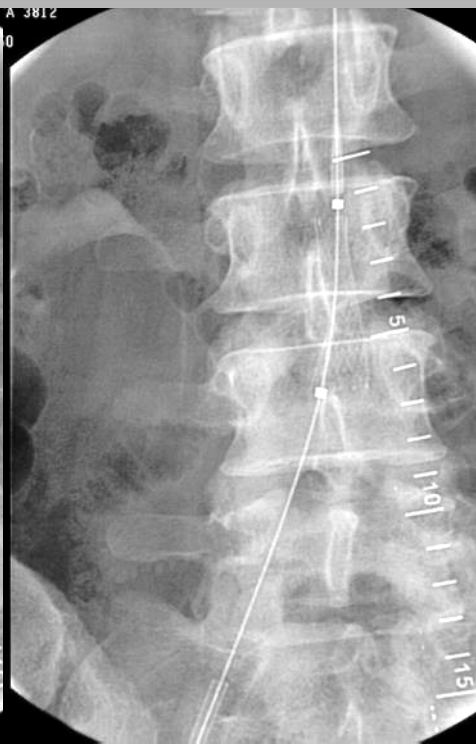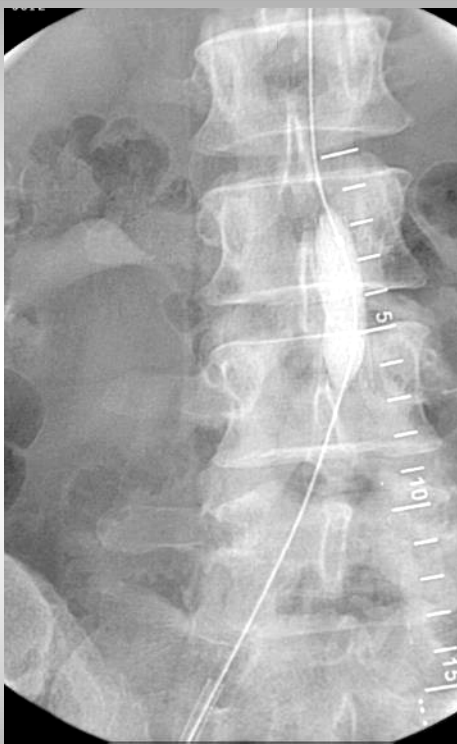






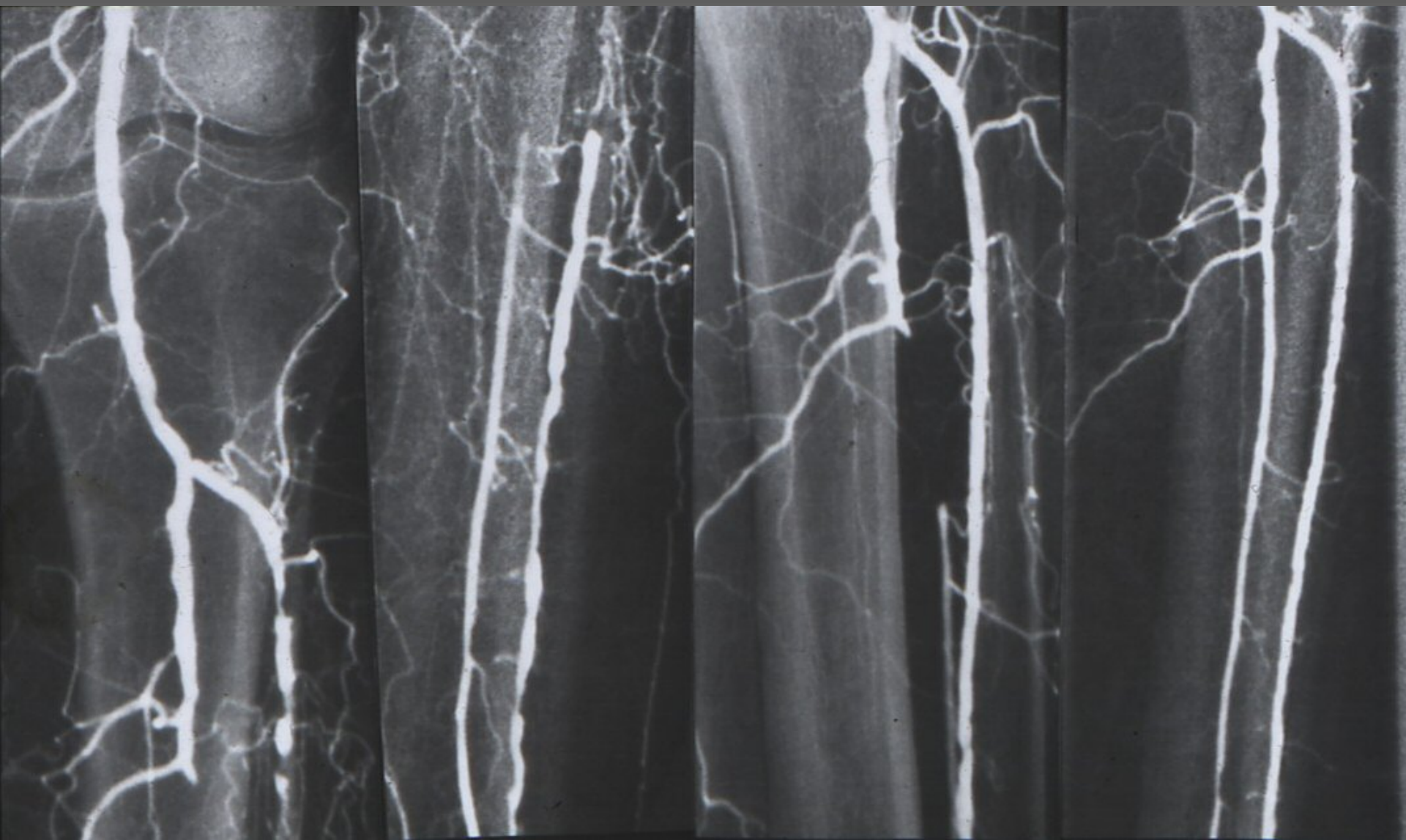


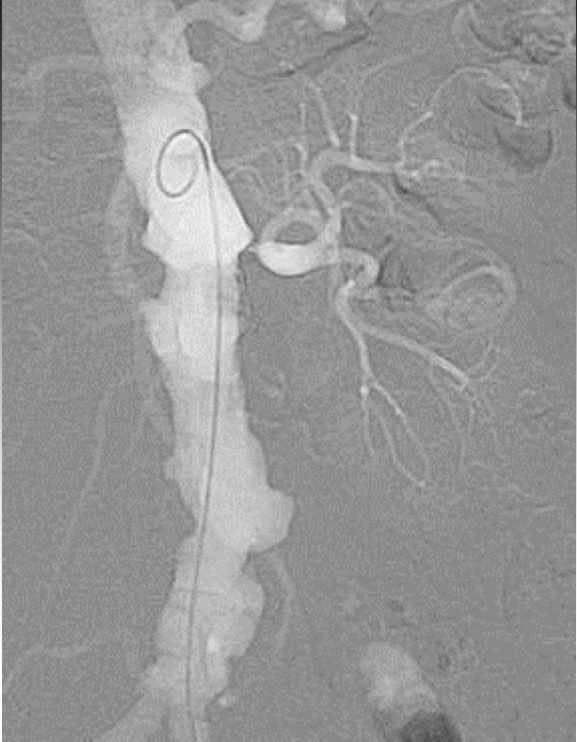






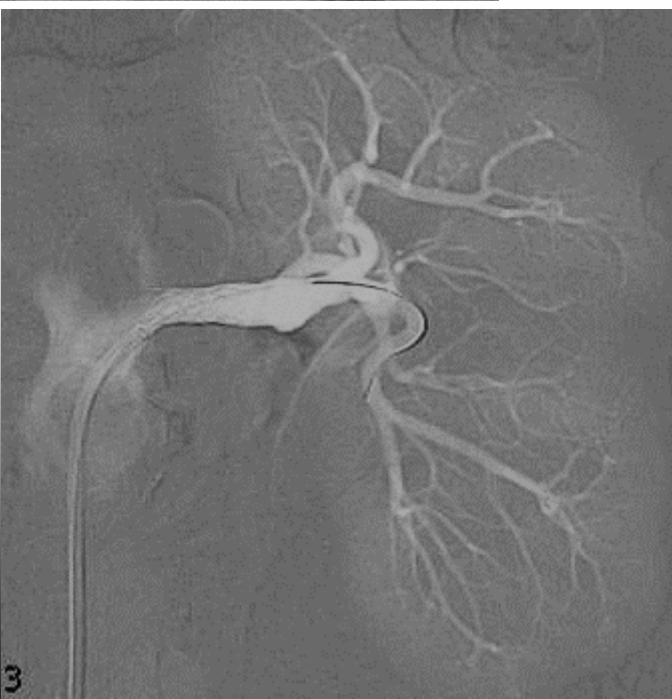
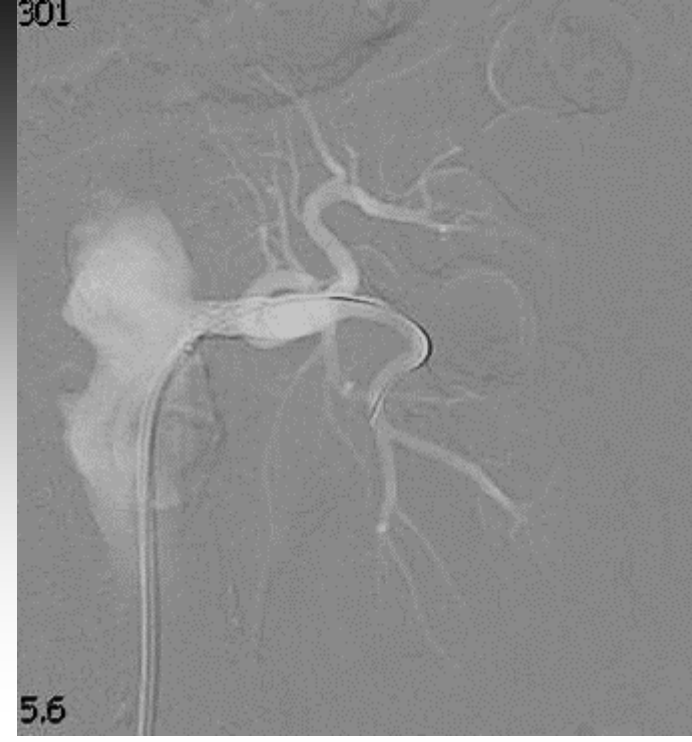
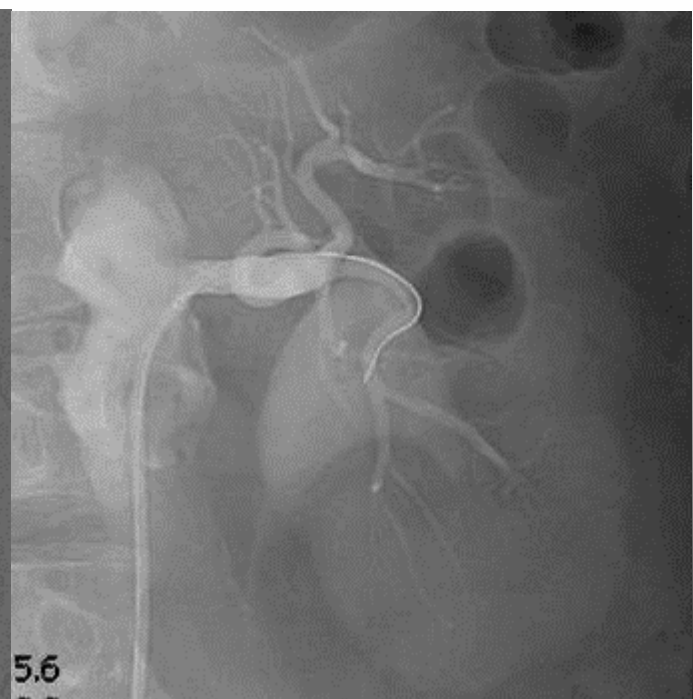301

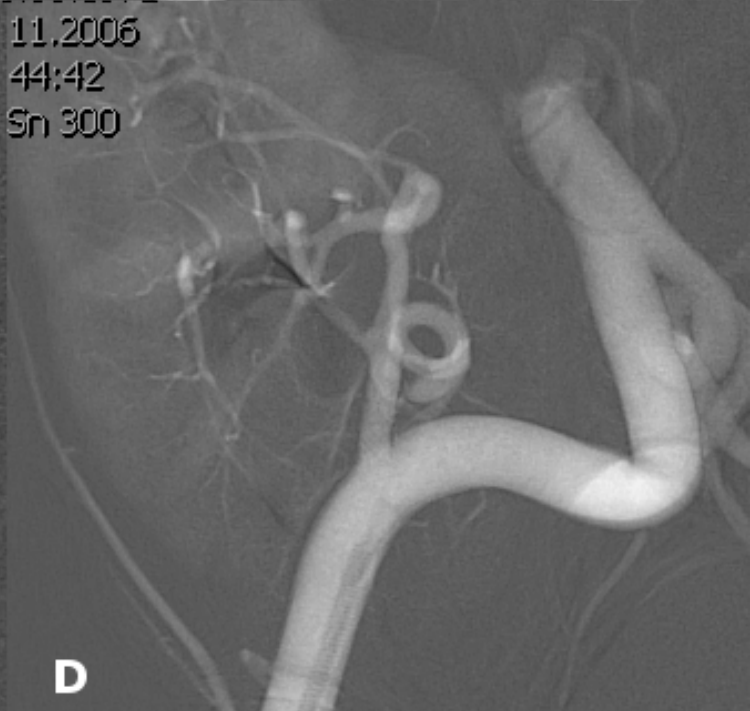
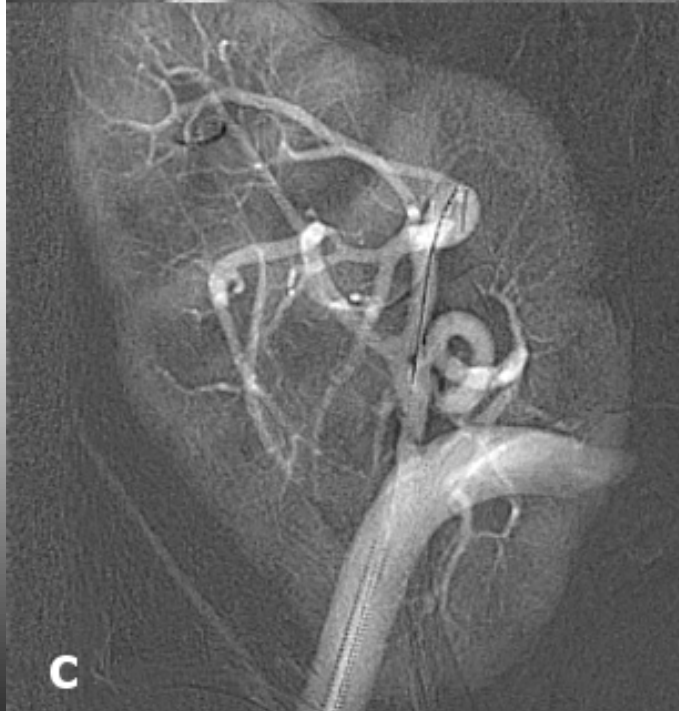
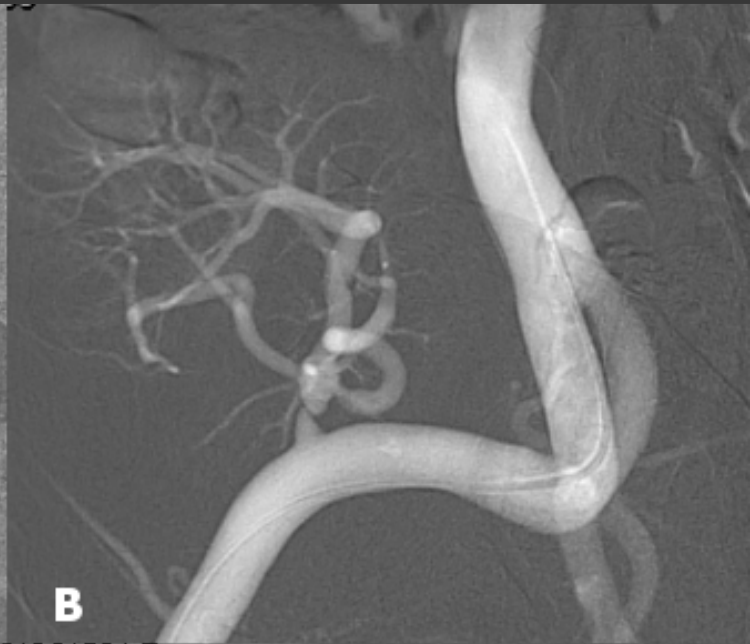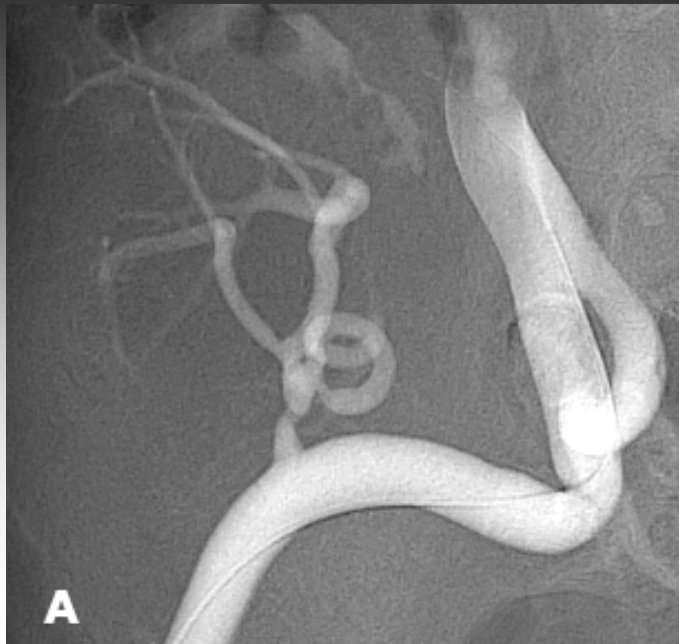5.6

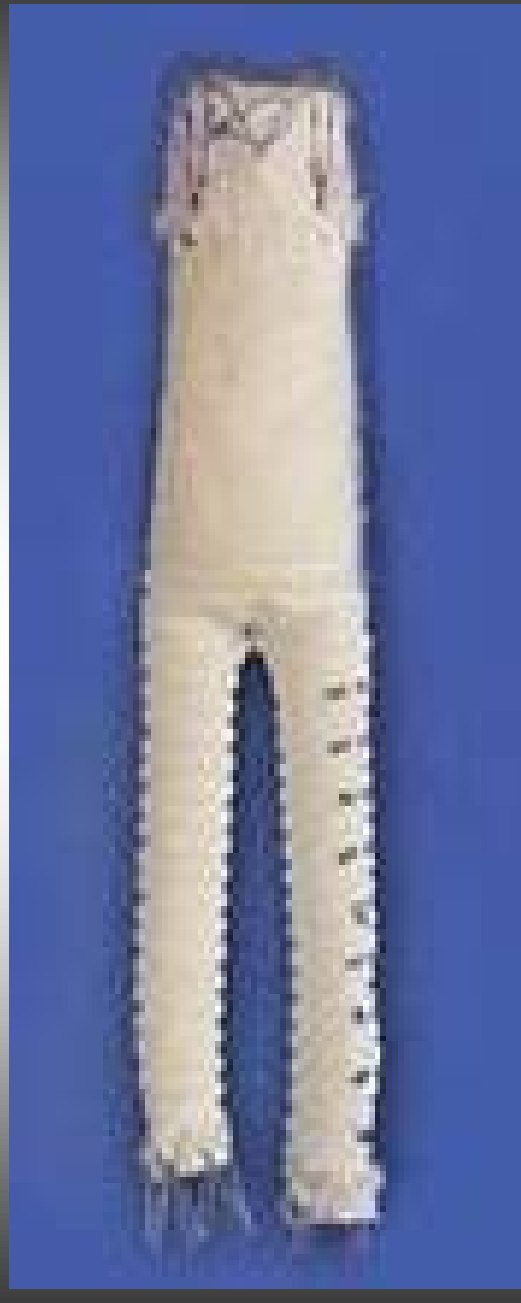
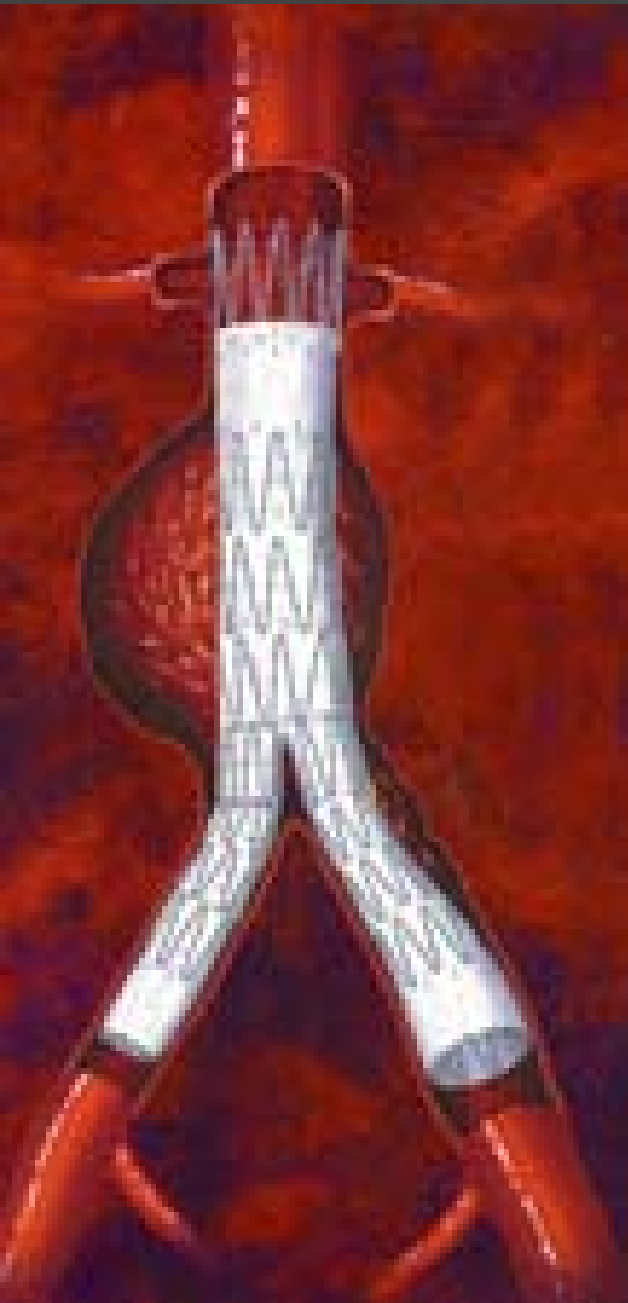
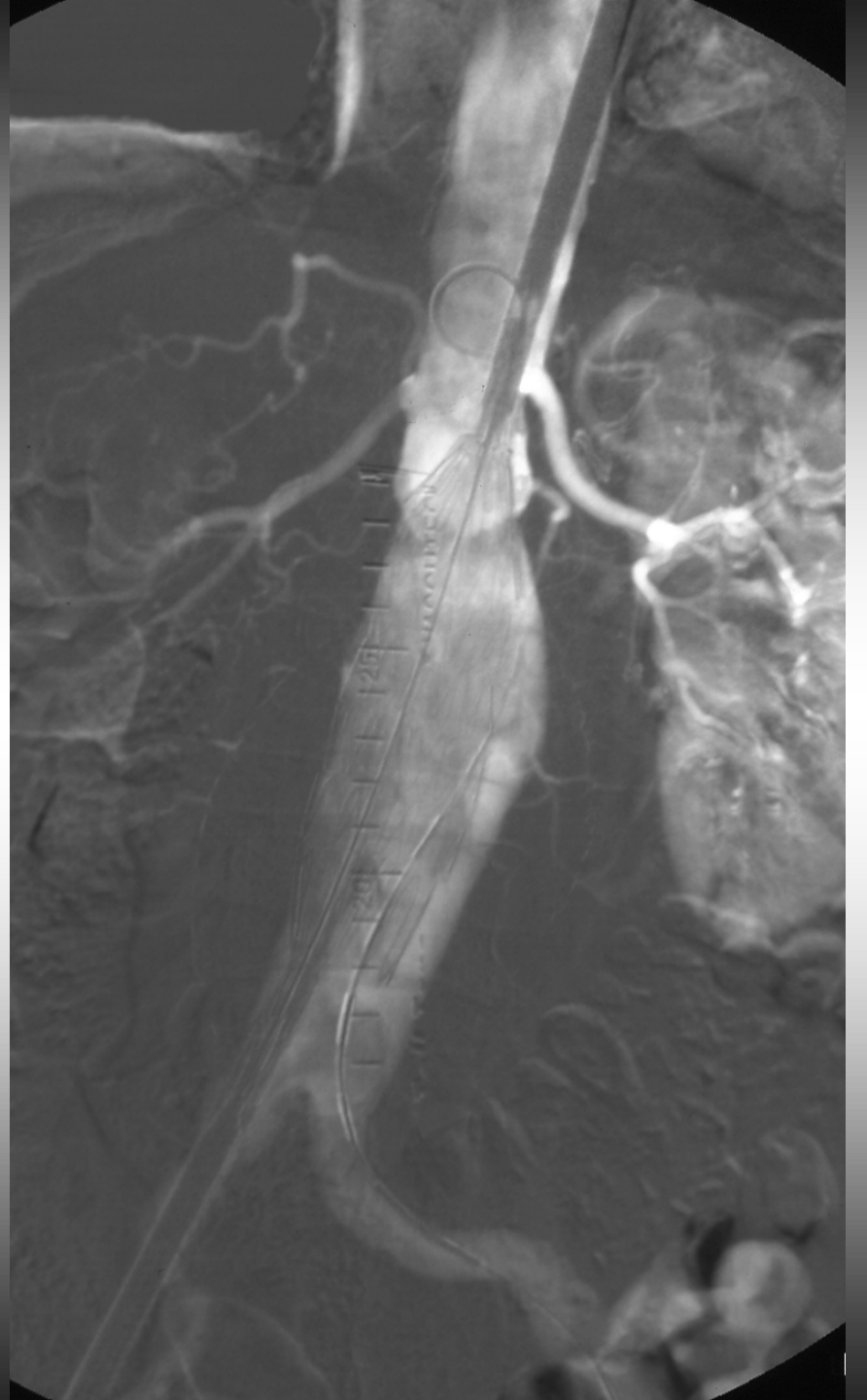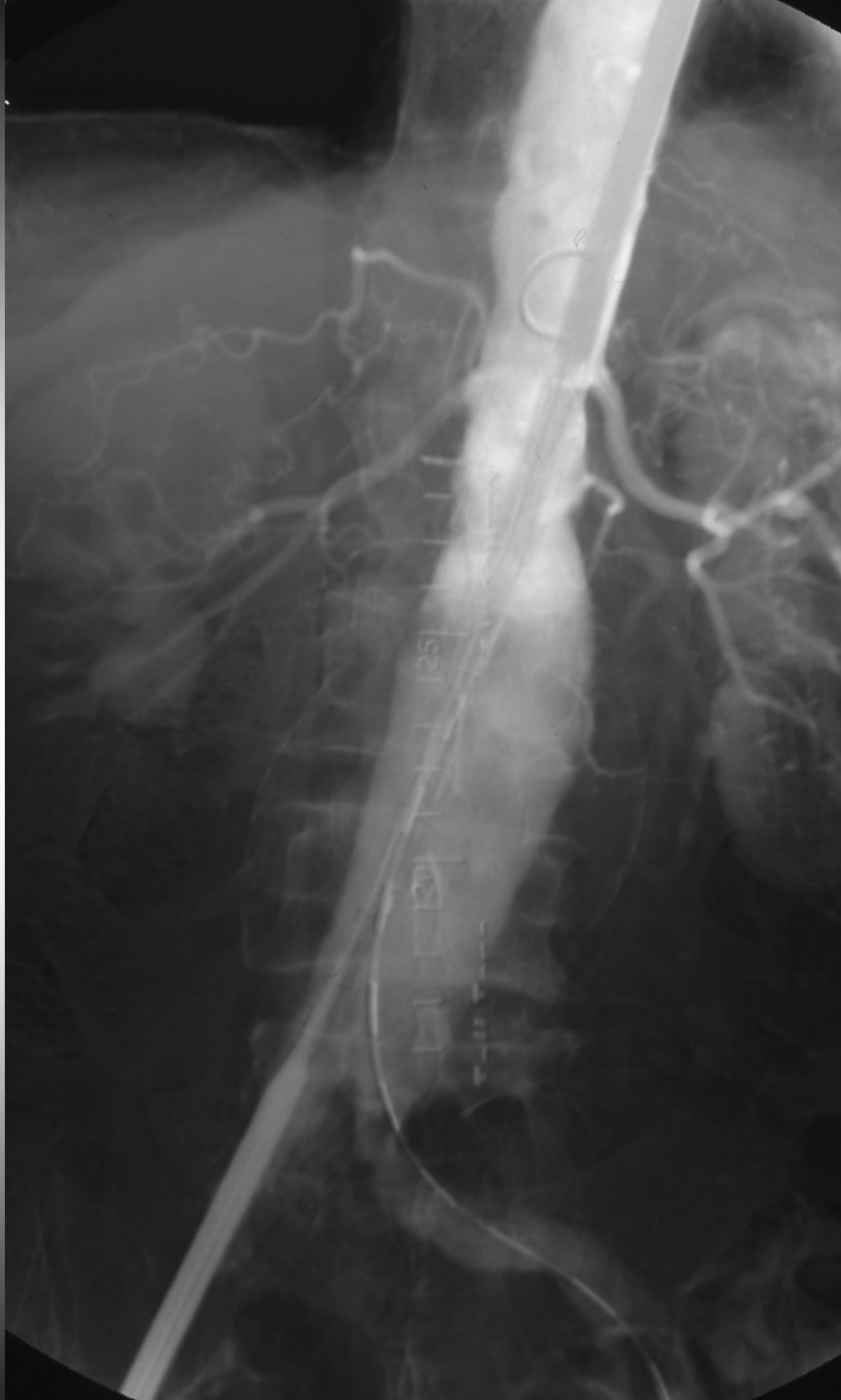3



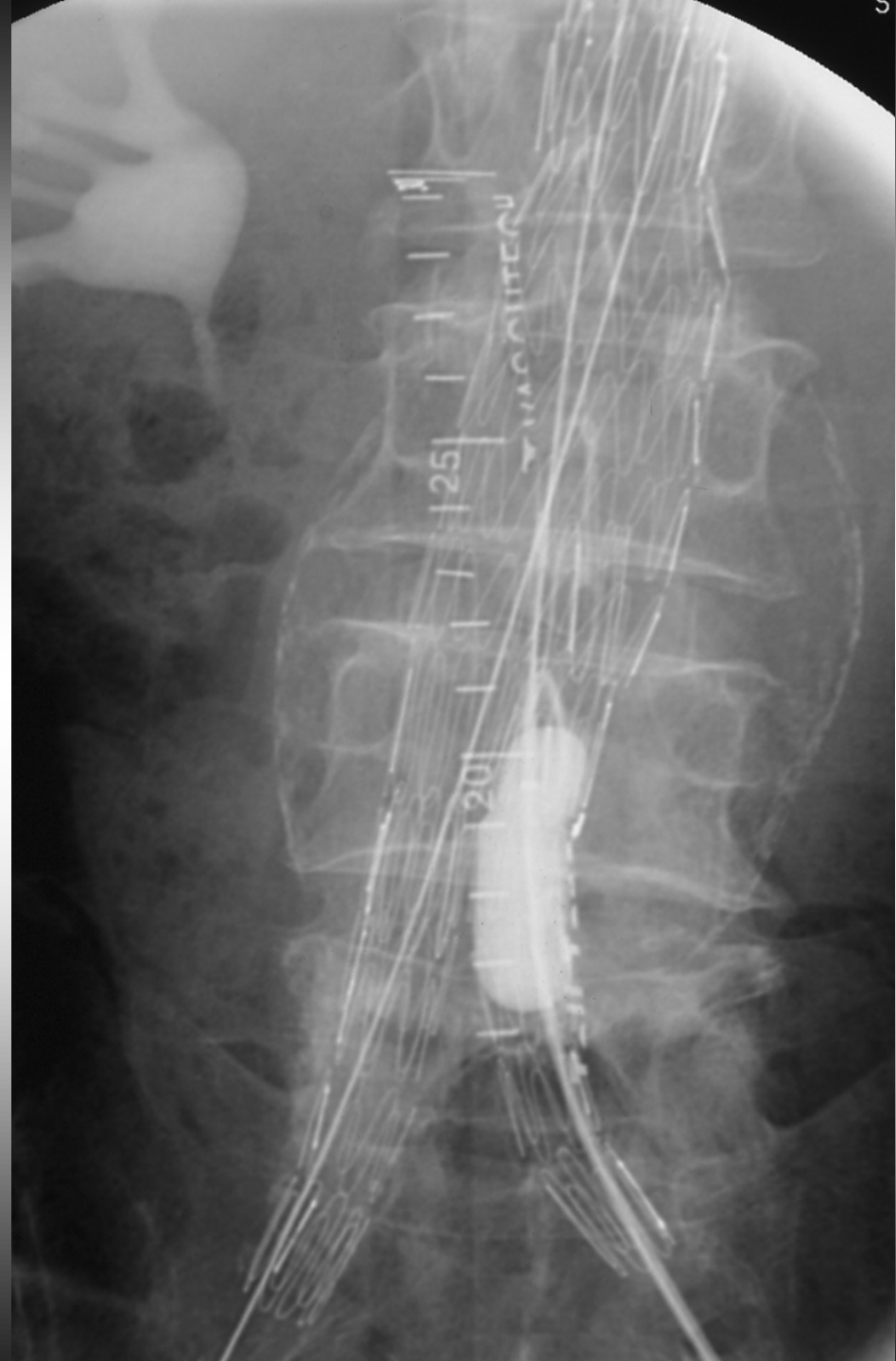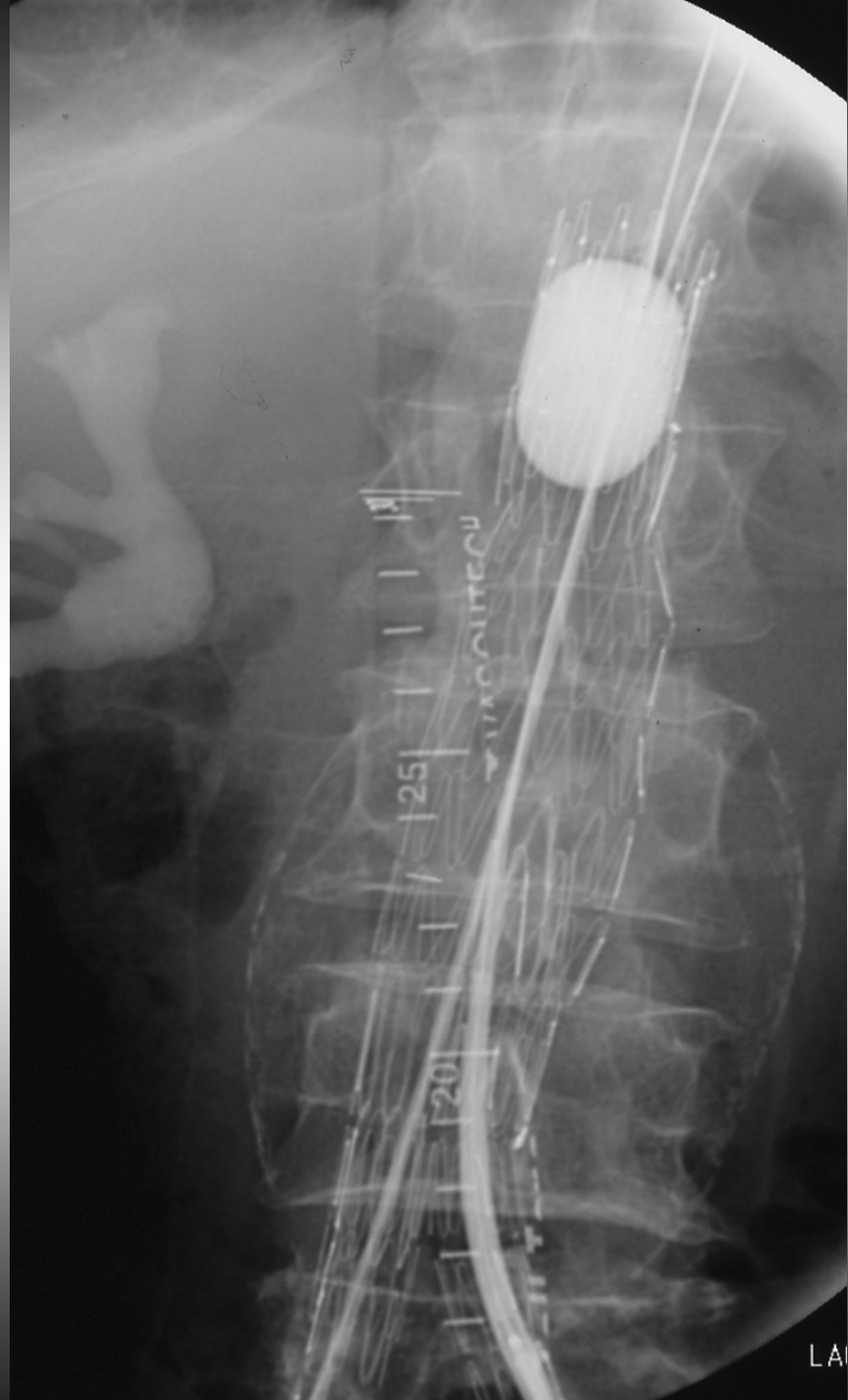
5.6

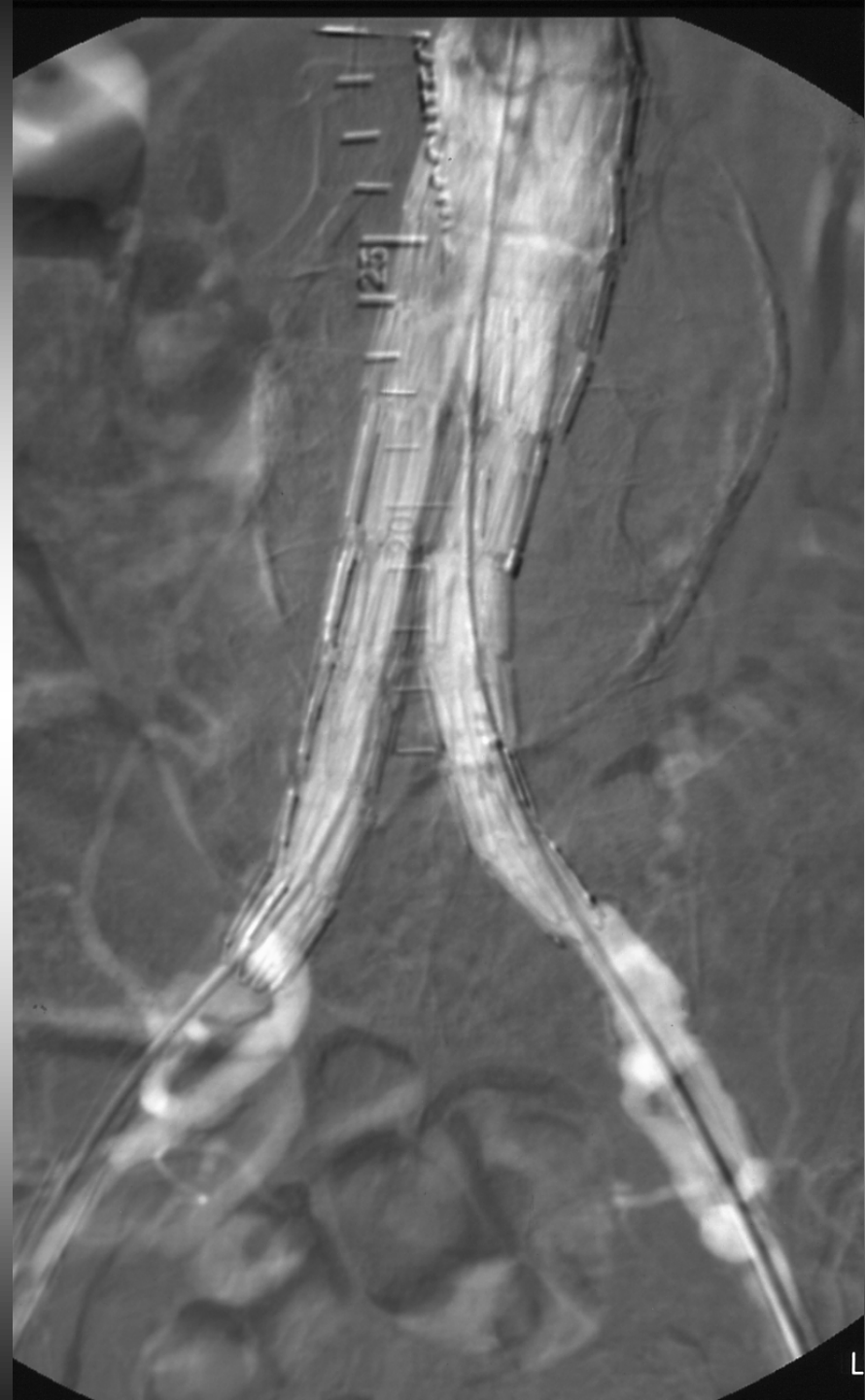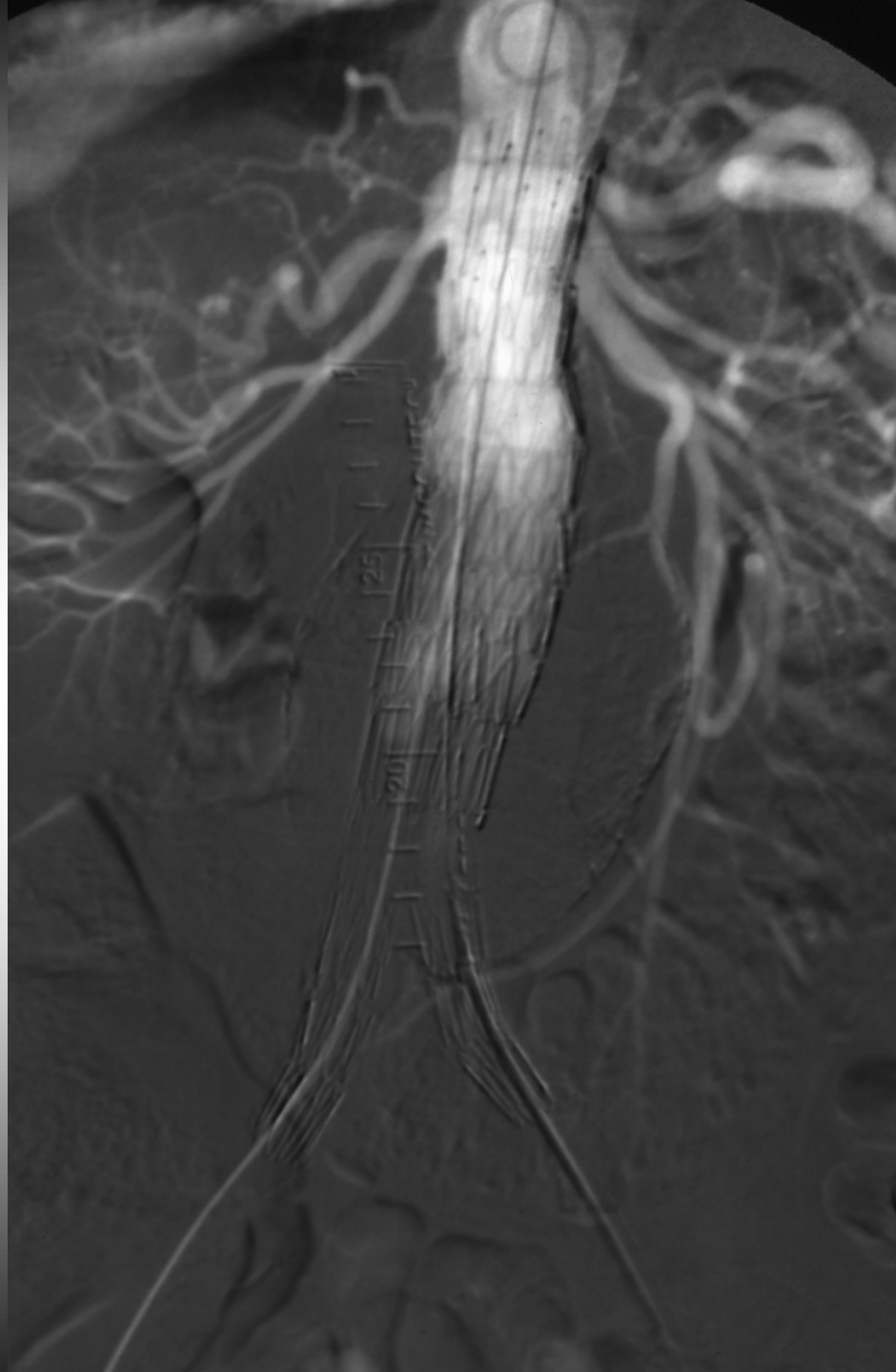


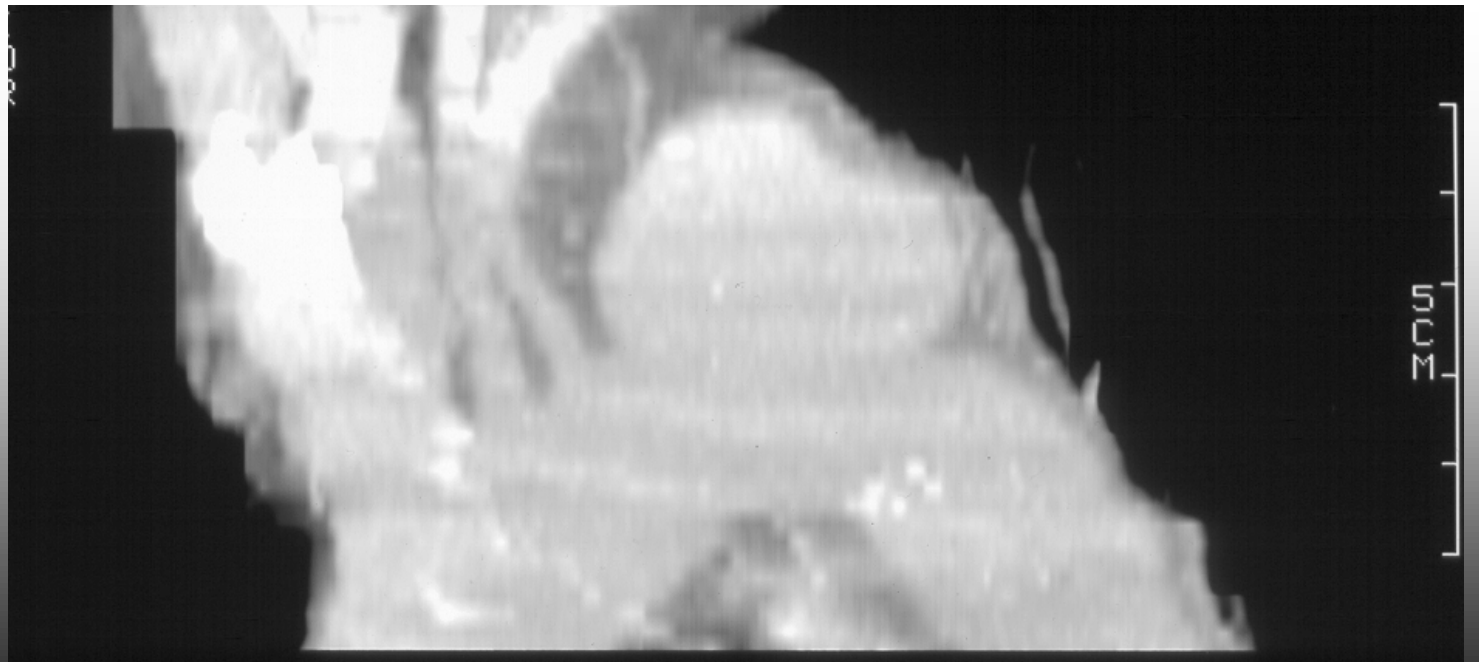
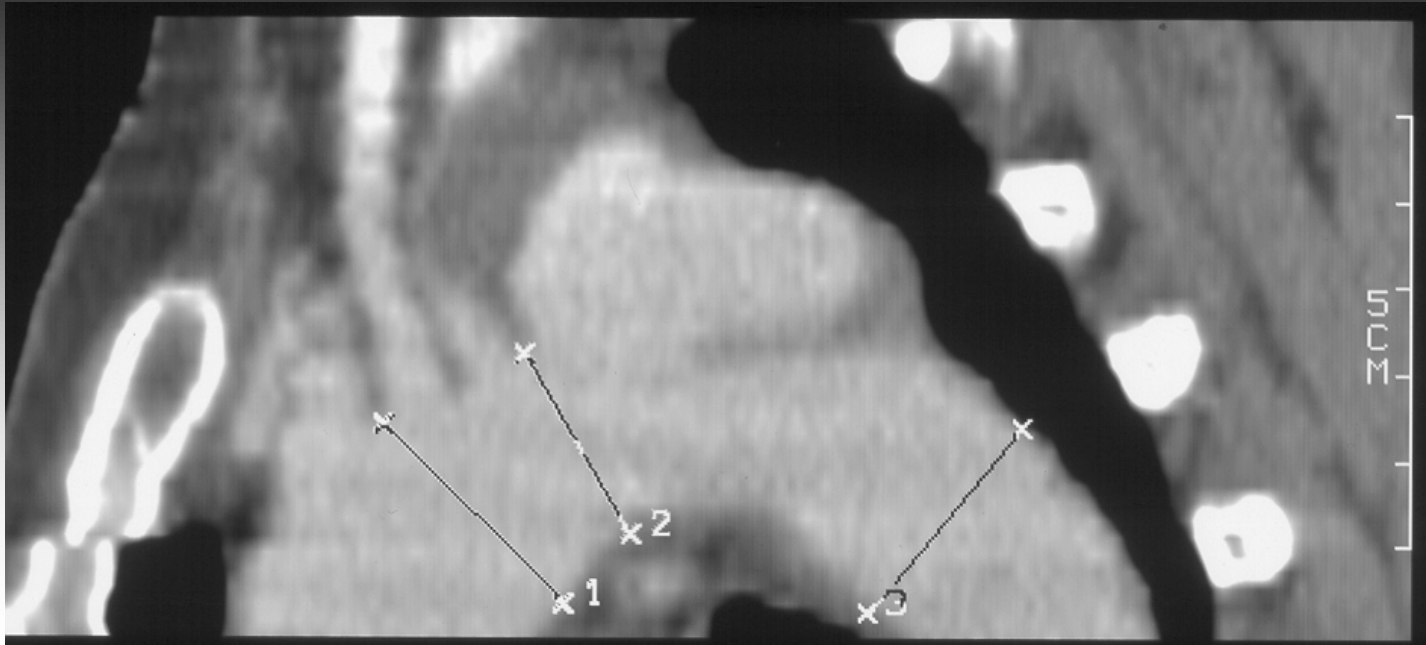




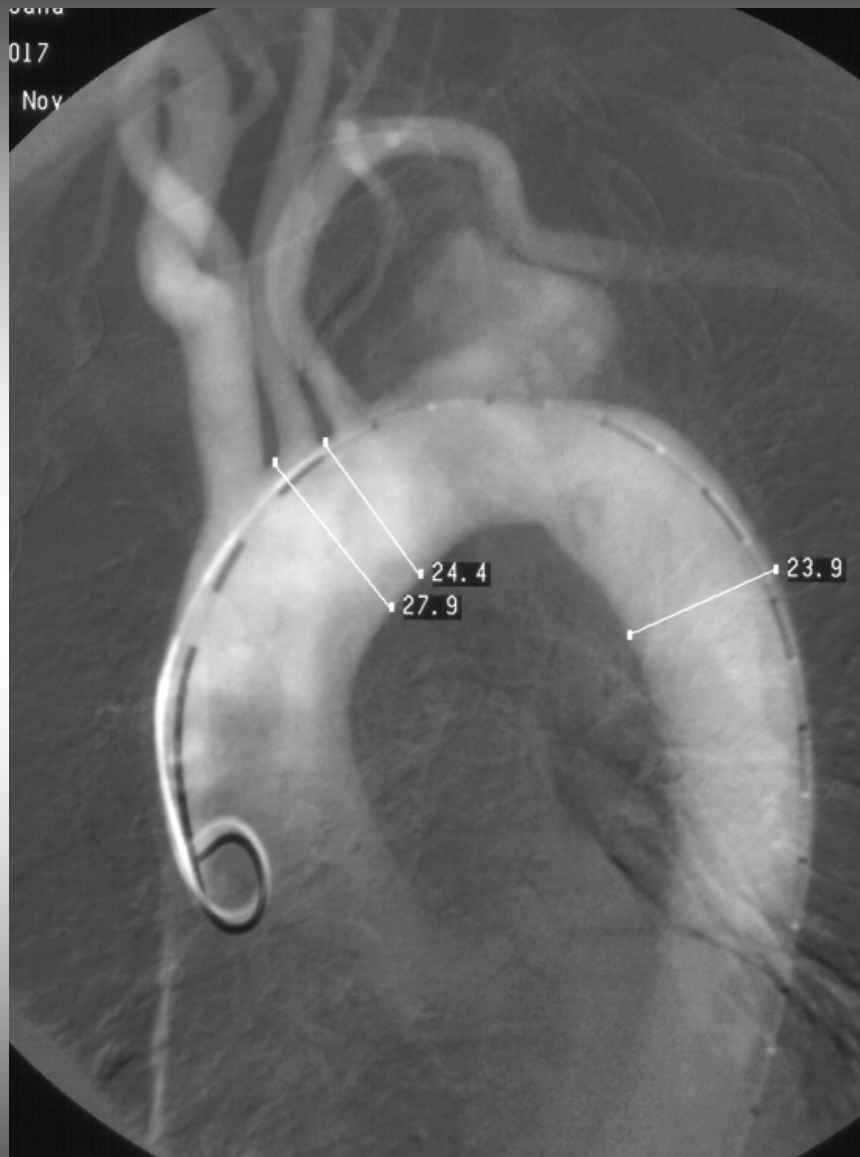





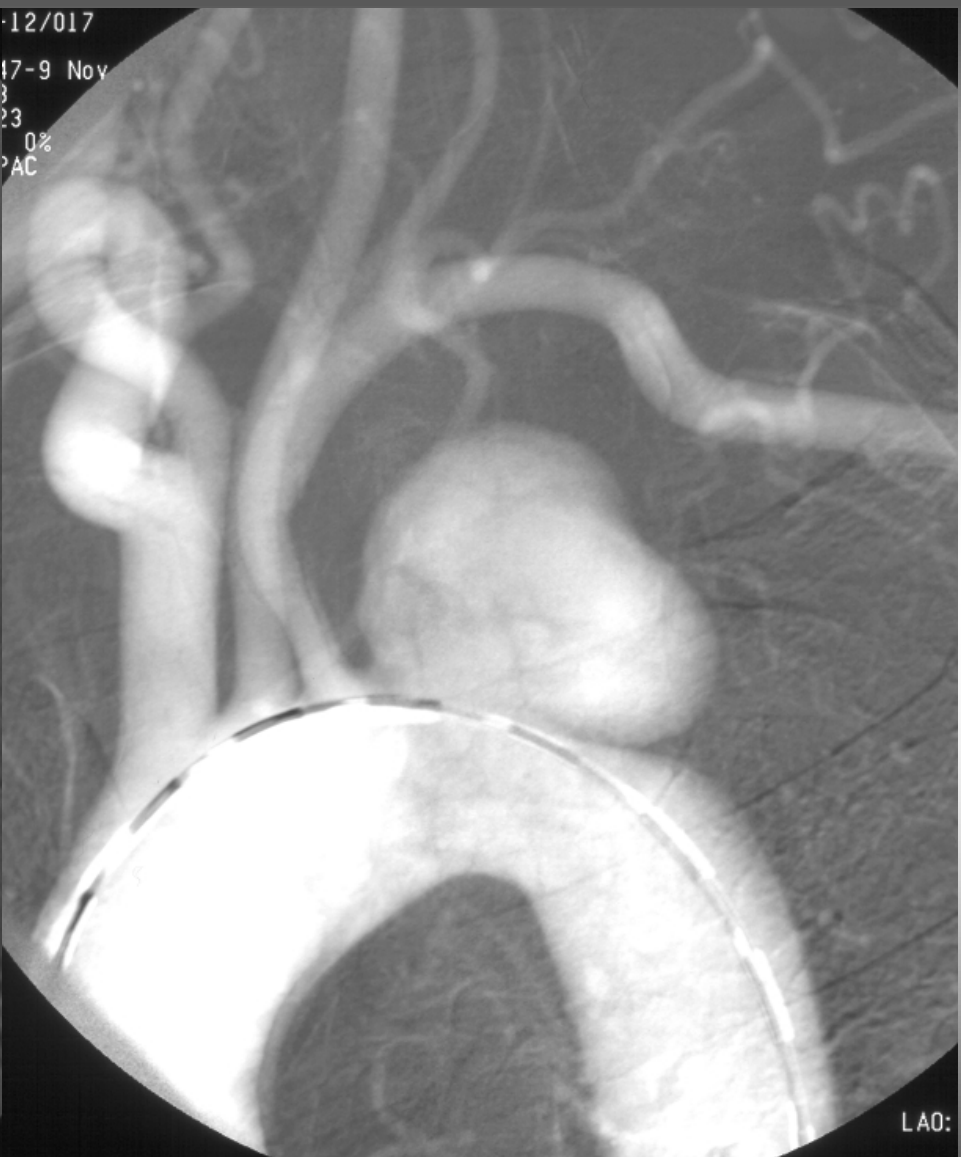


017  
Nov



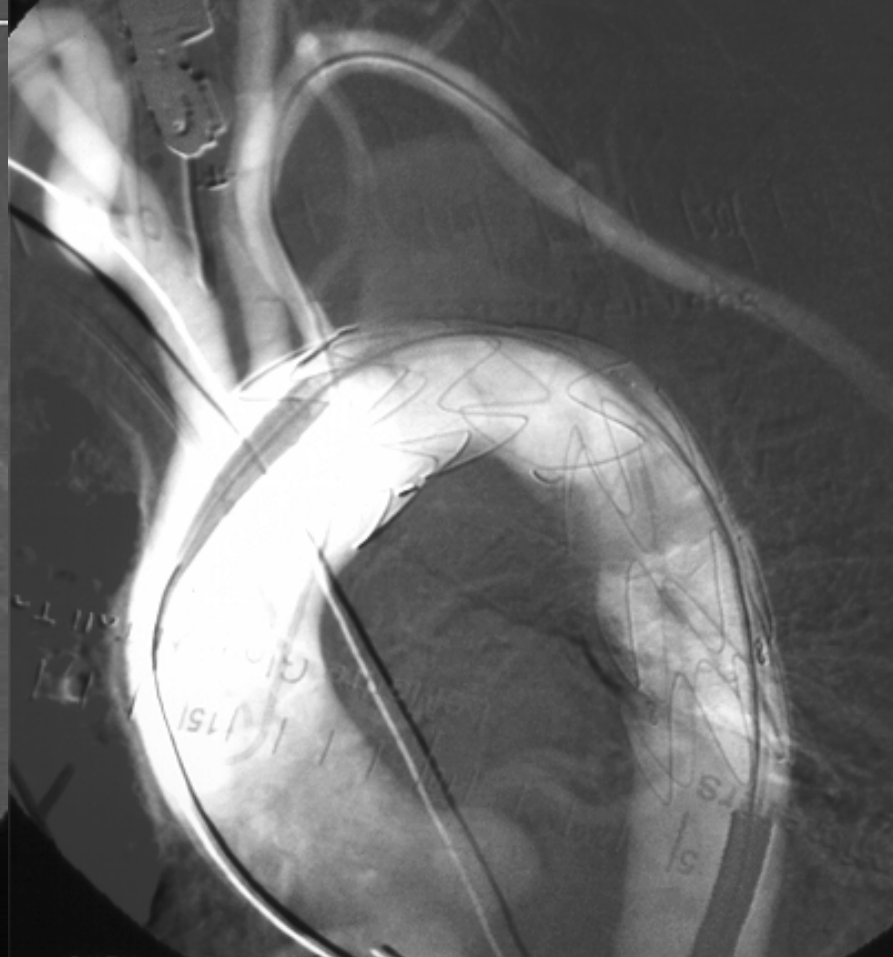
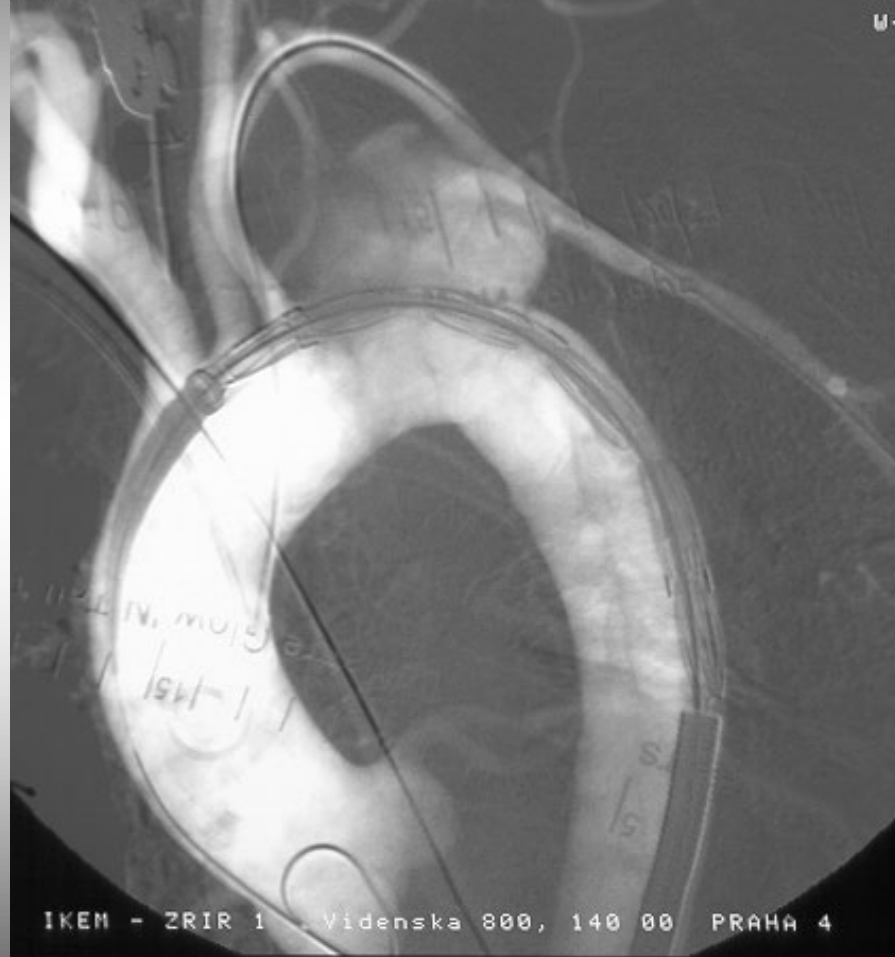12/017  
17-9 Nov  
3  
23  
0%  
PAC



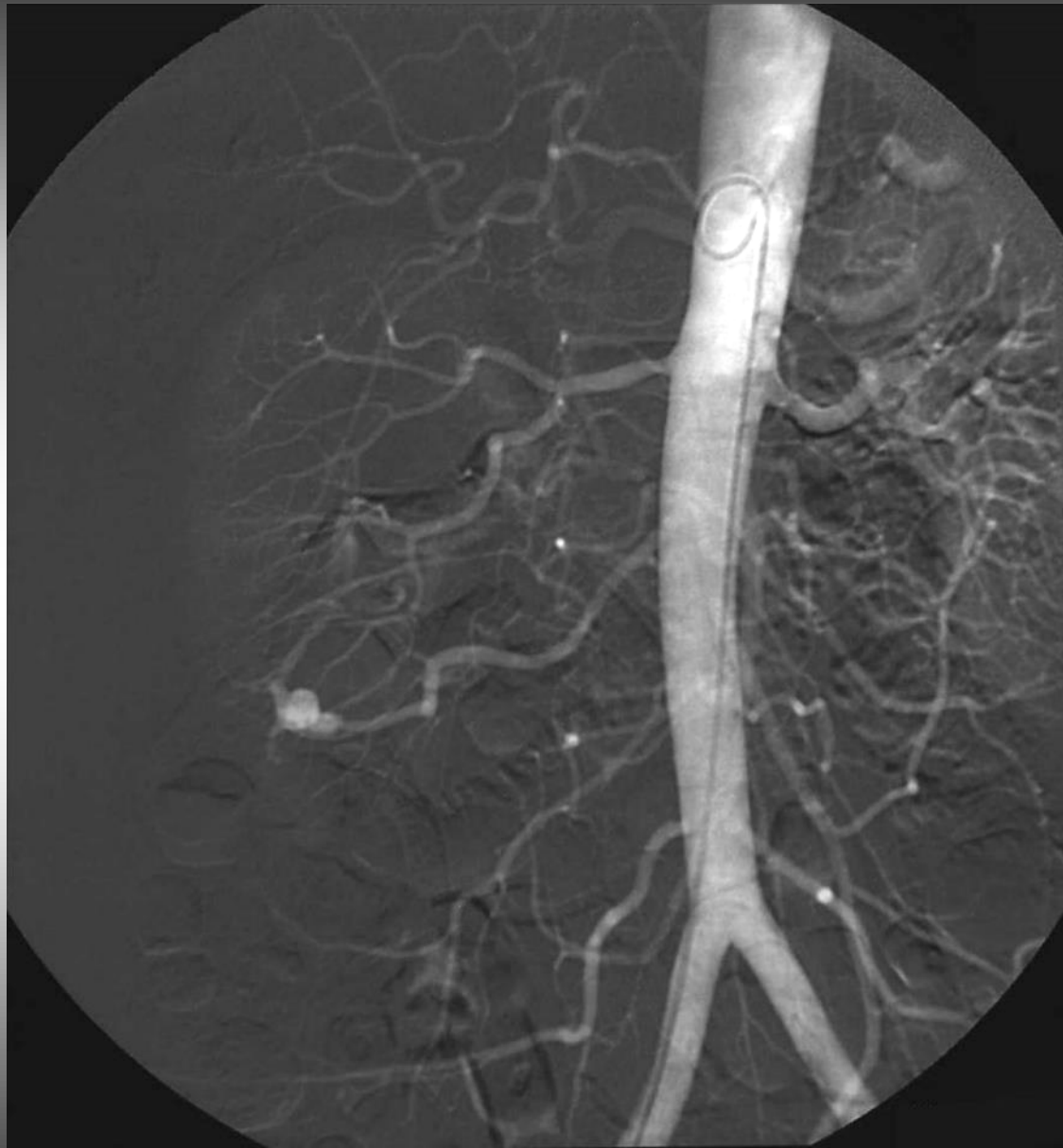LAO:

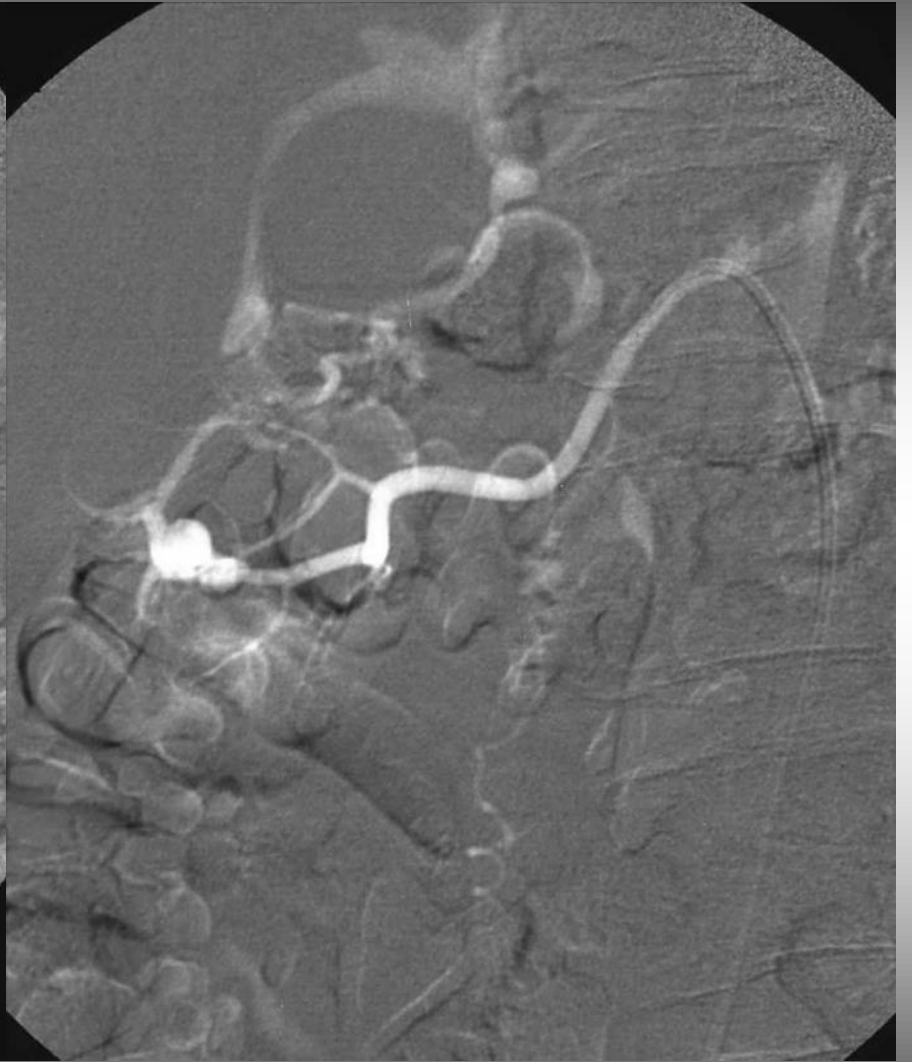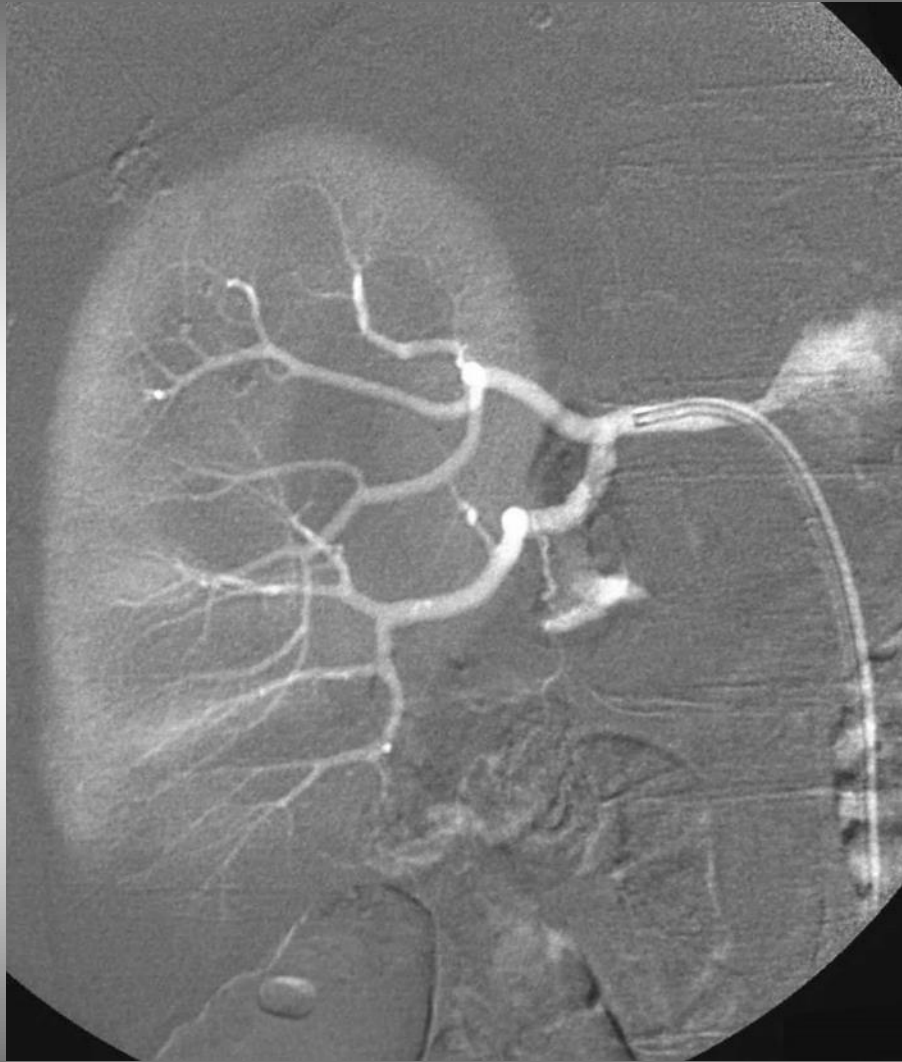UVH JARA  
2/017  
4  
4/1  
2/1

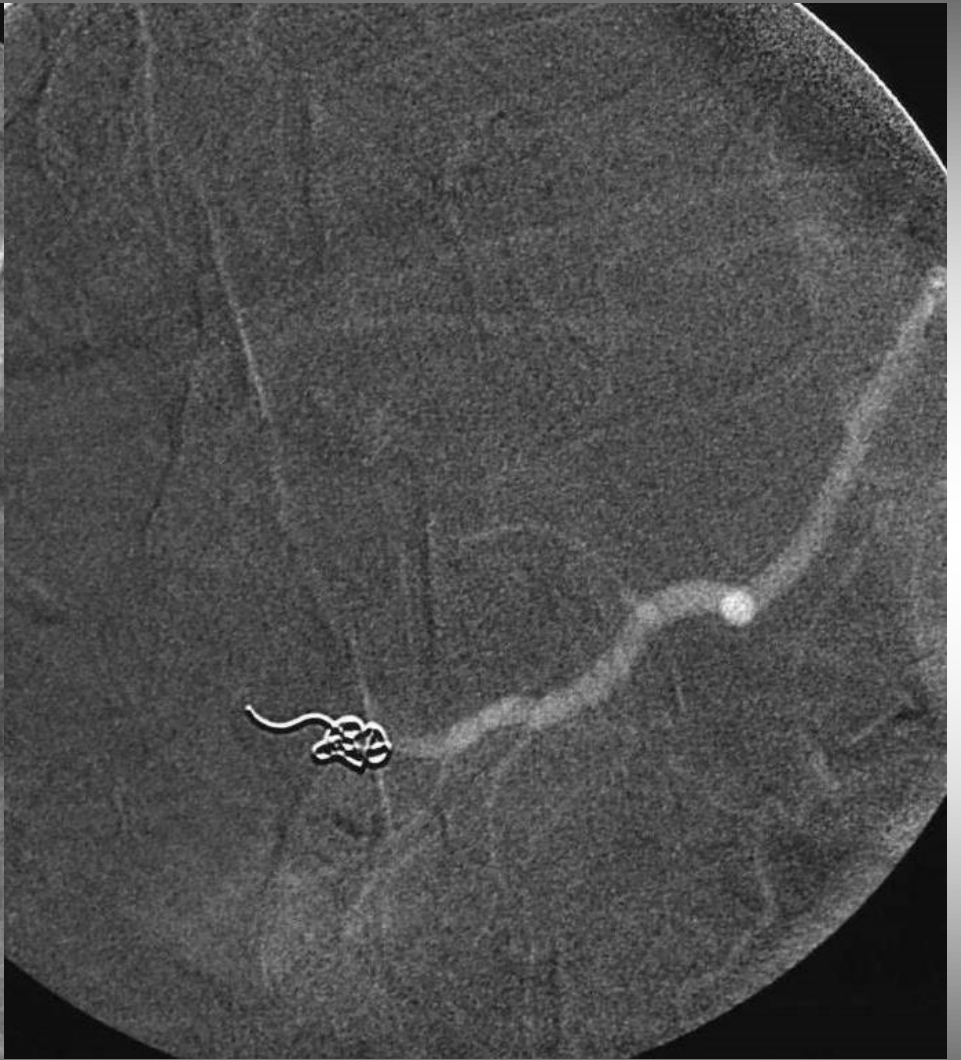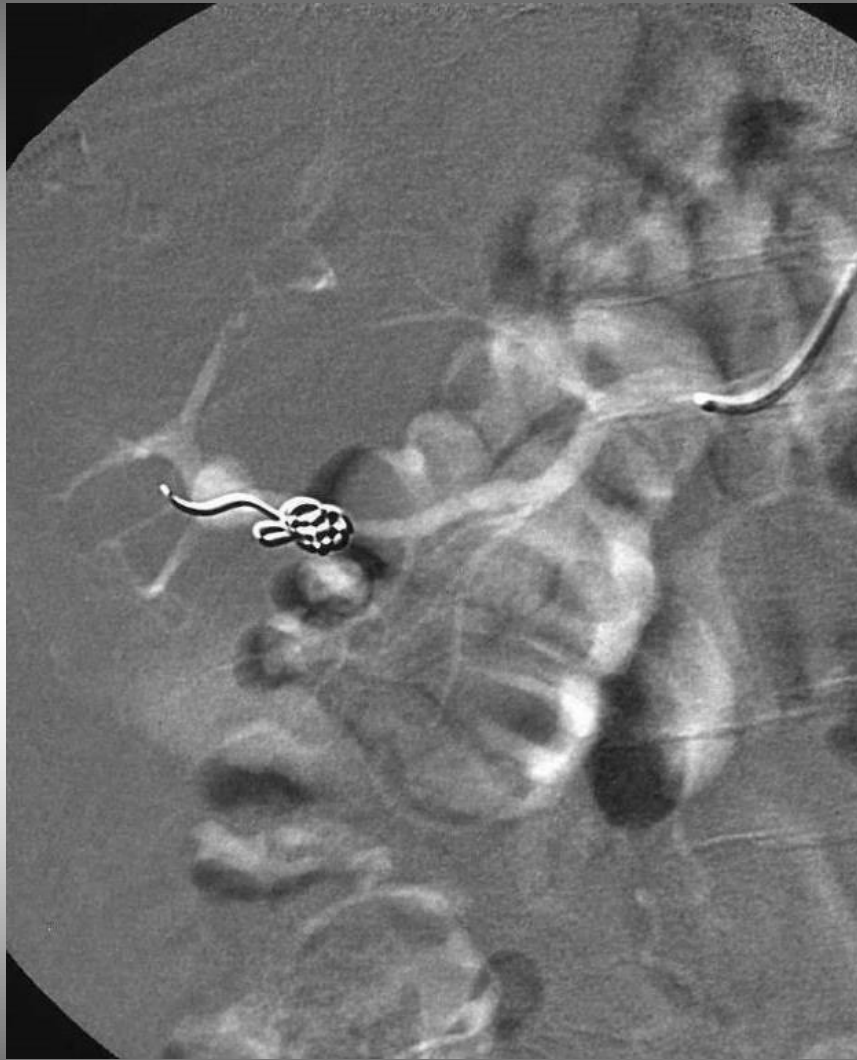UBLOUKOVA JARA  
31712/017  
1P14  
PH 5/1  
M-11/1  
M-

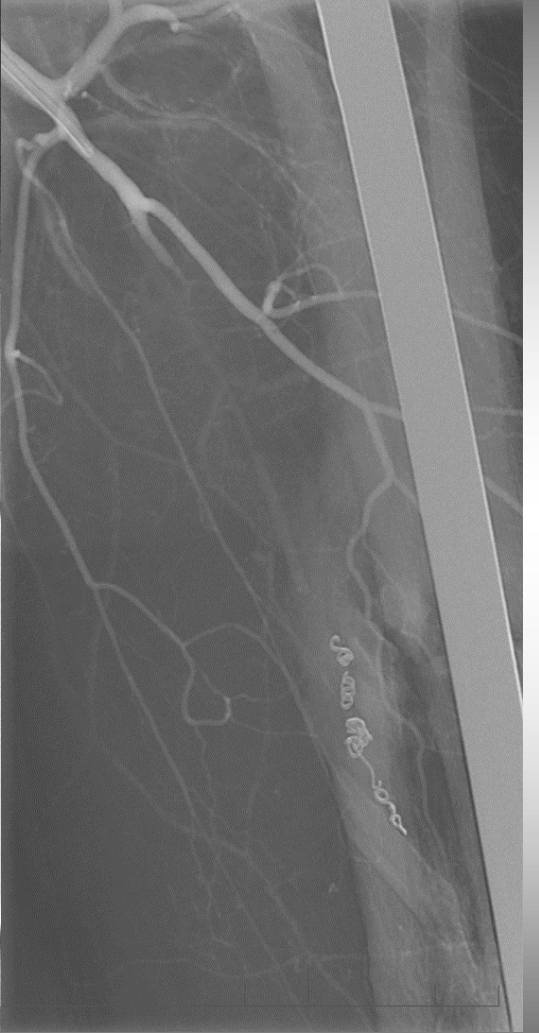
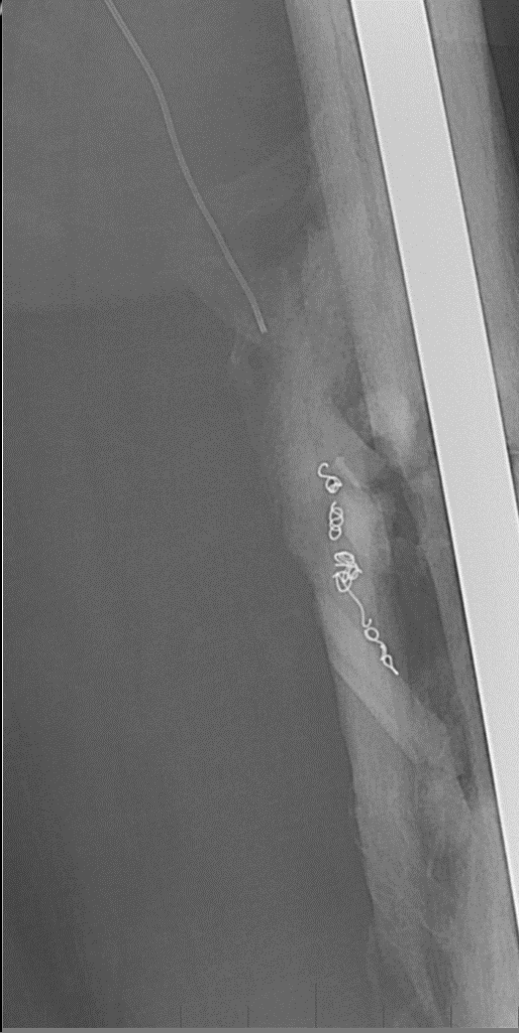
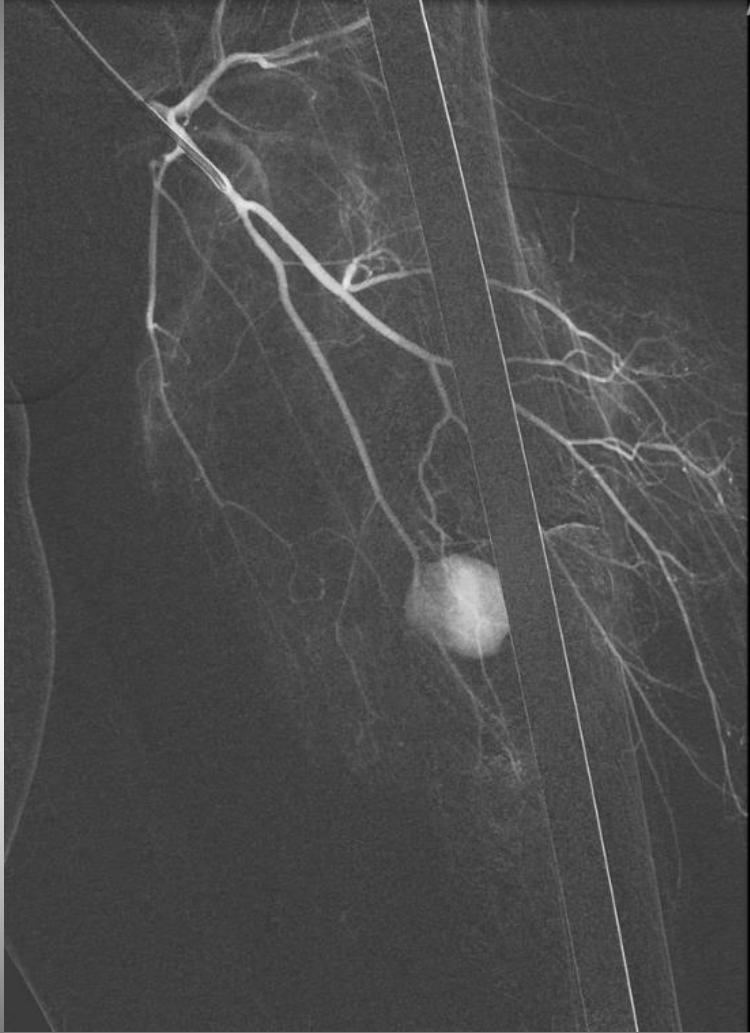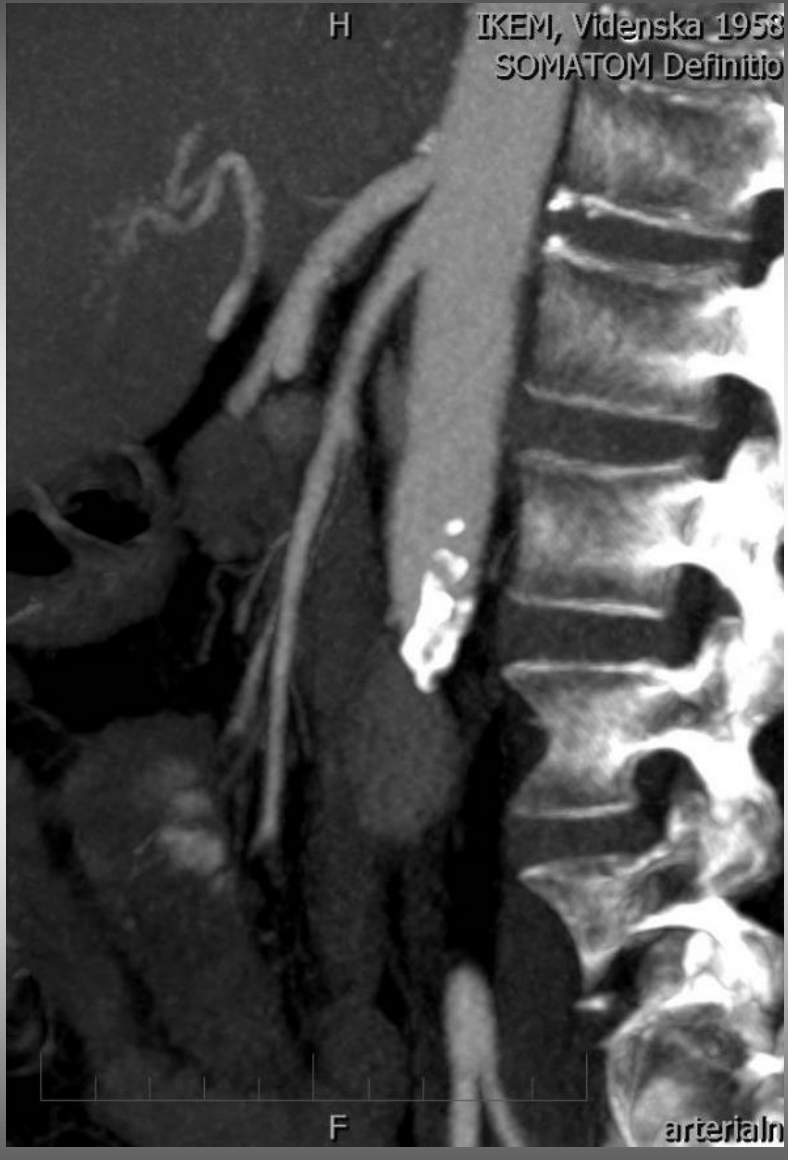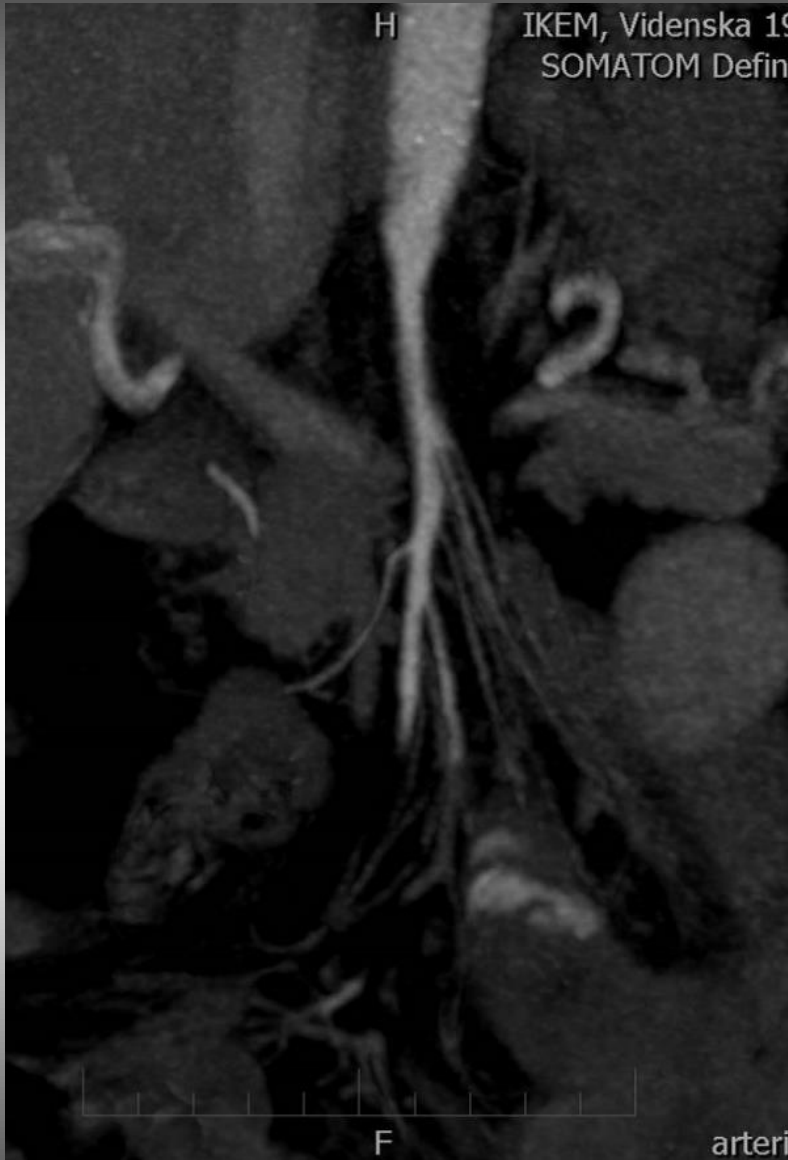




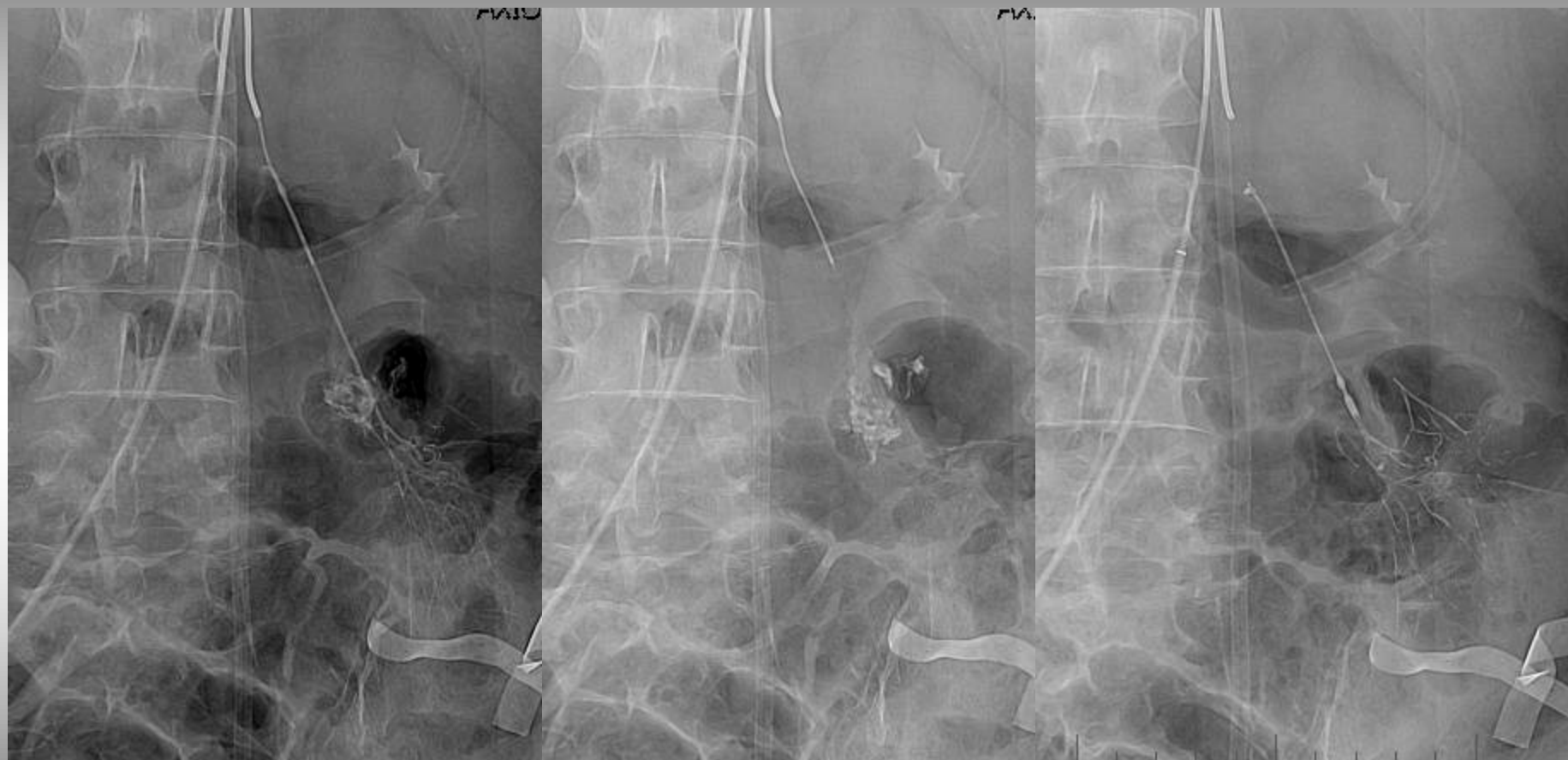




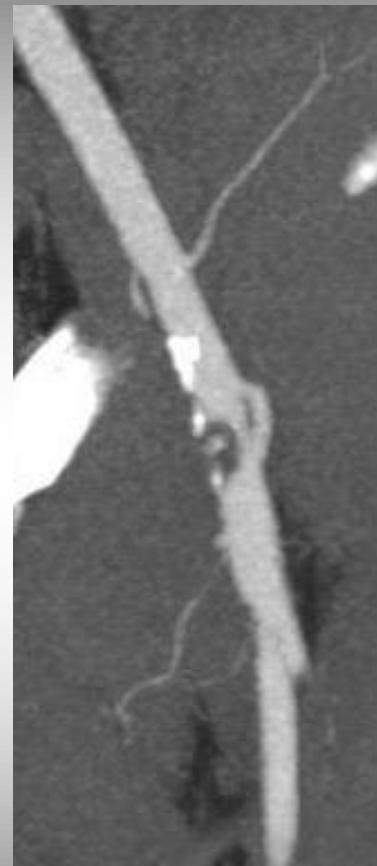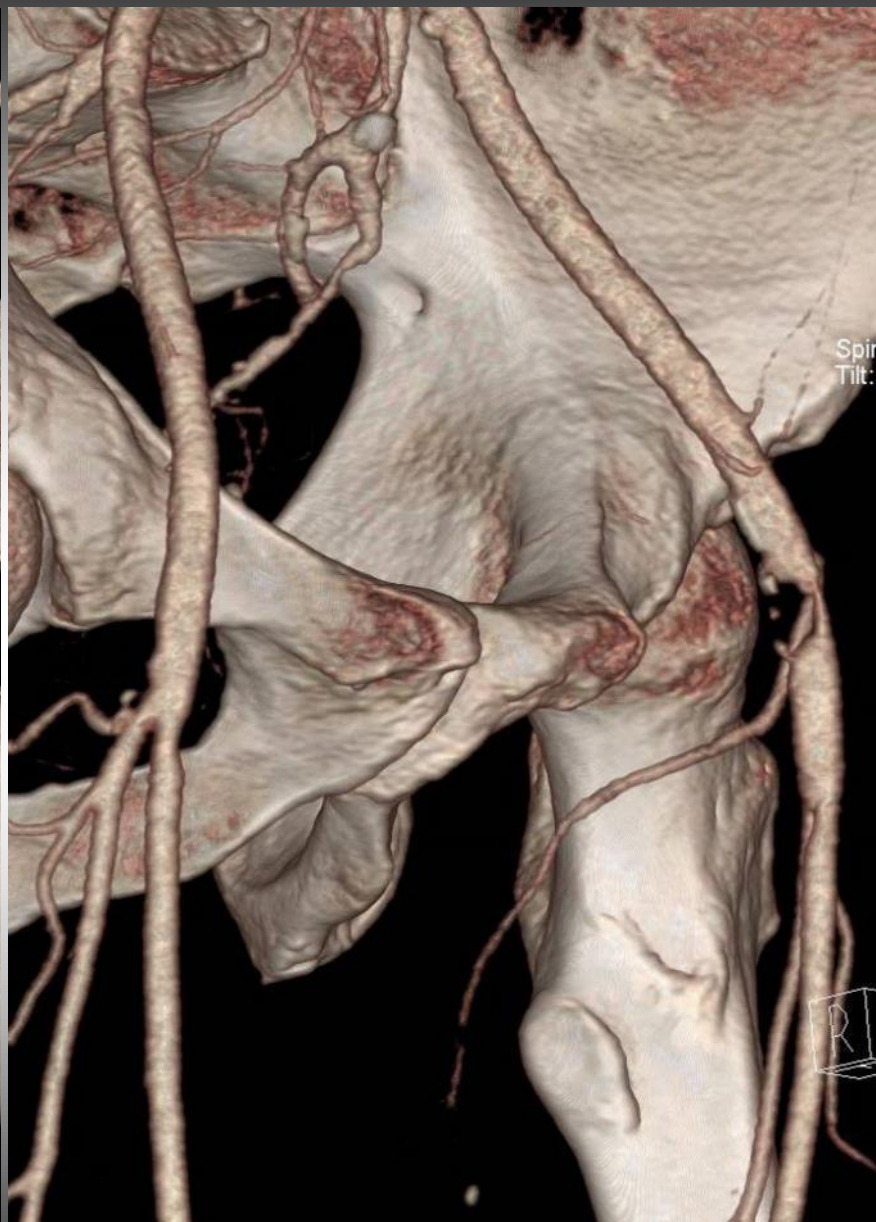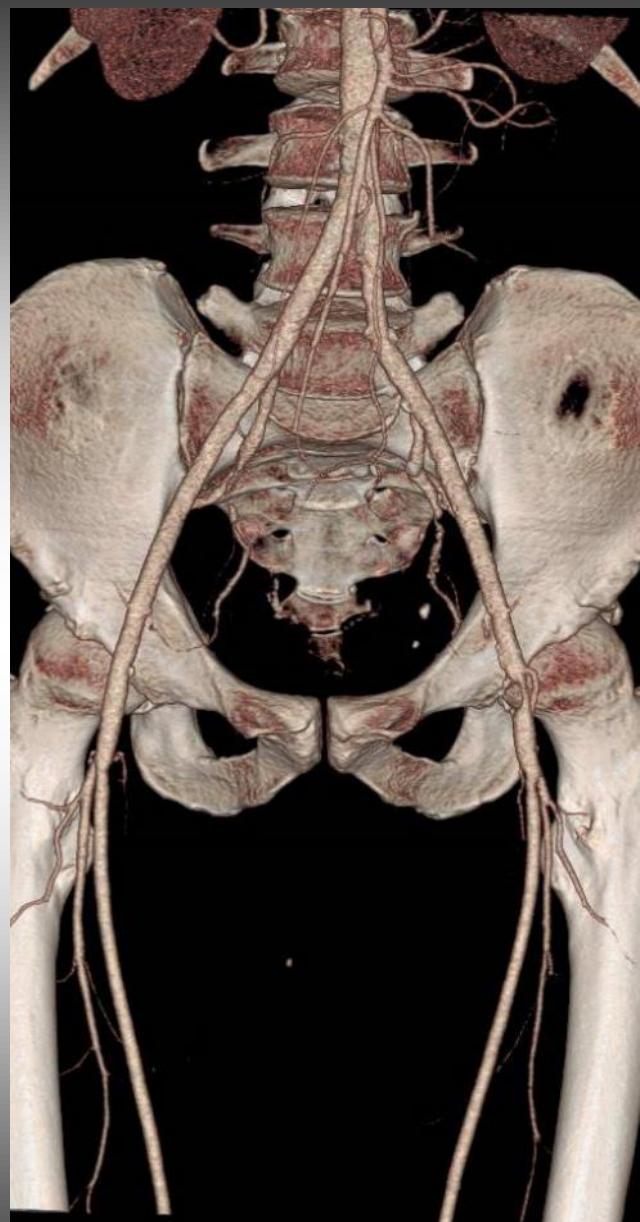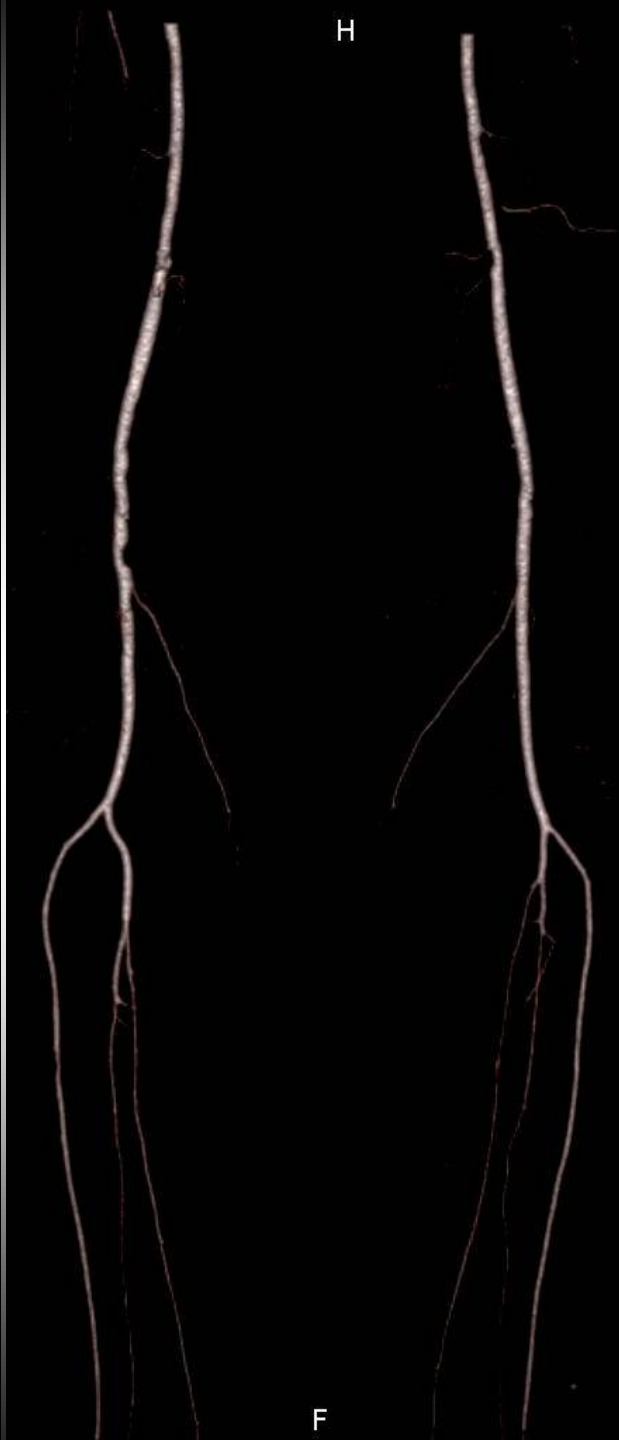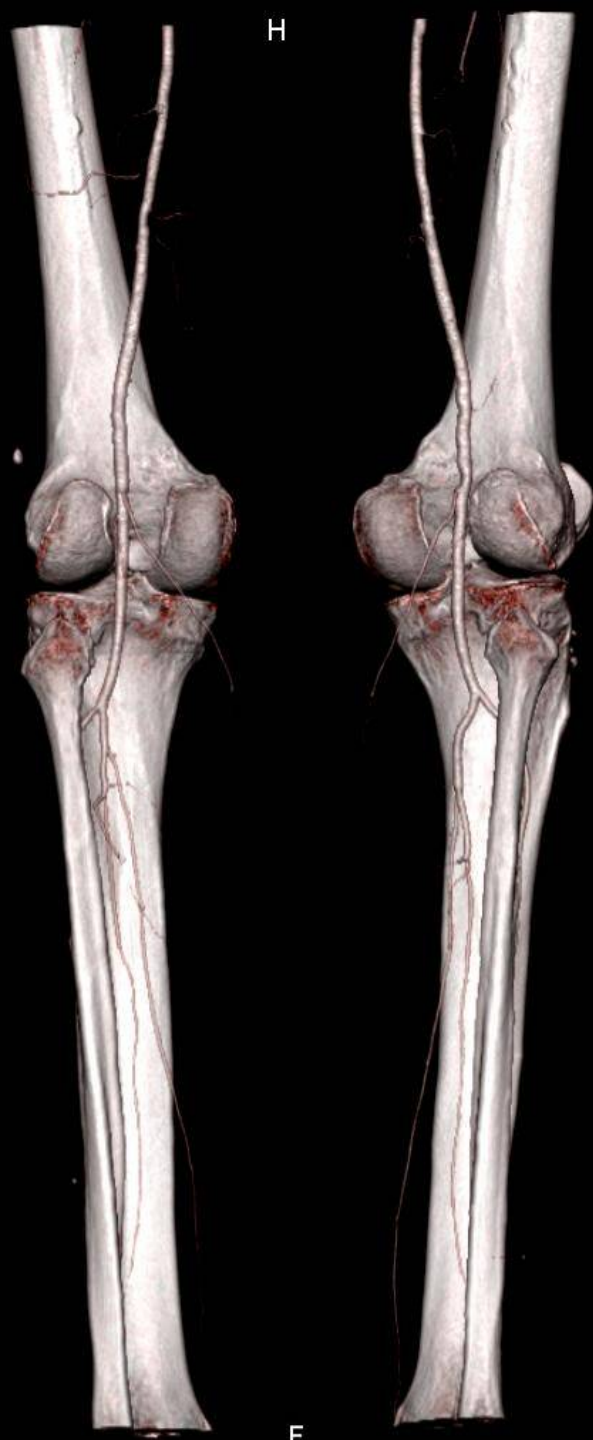




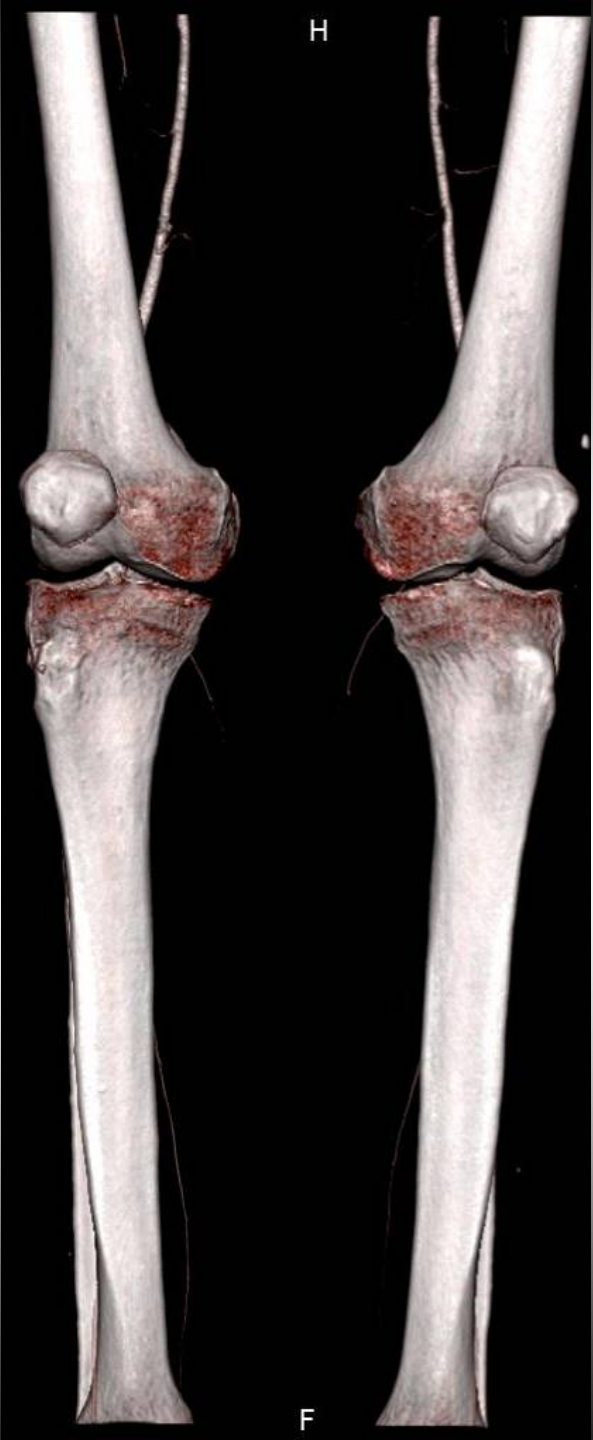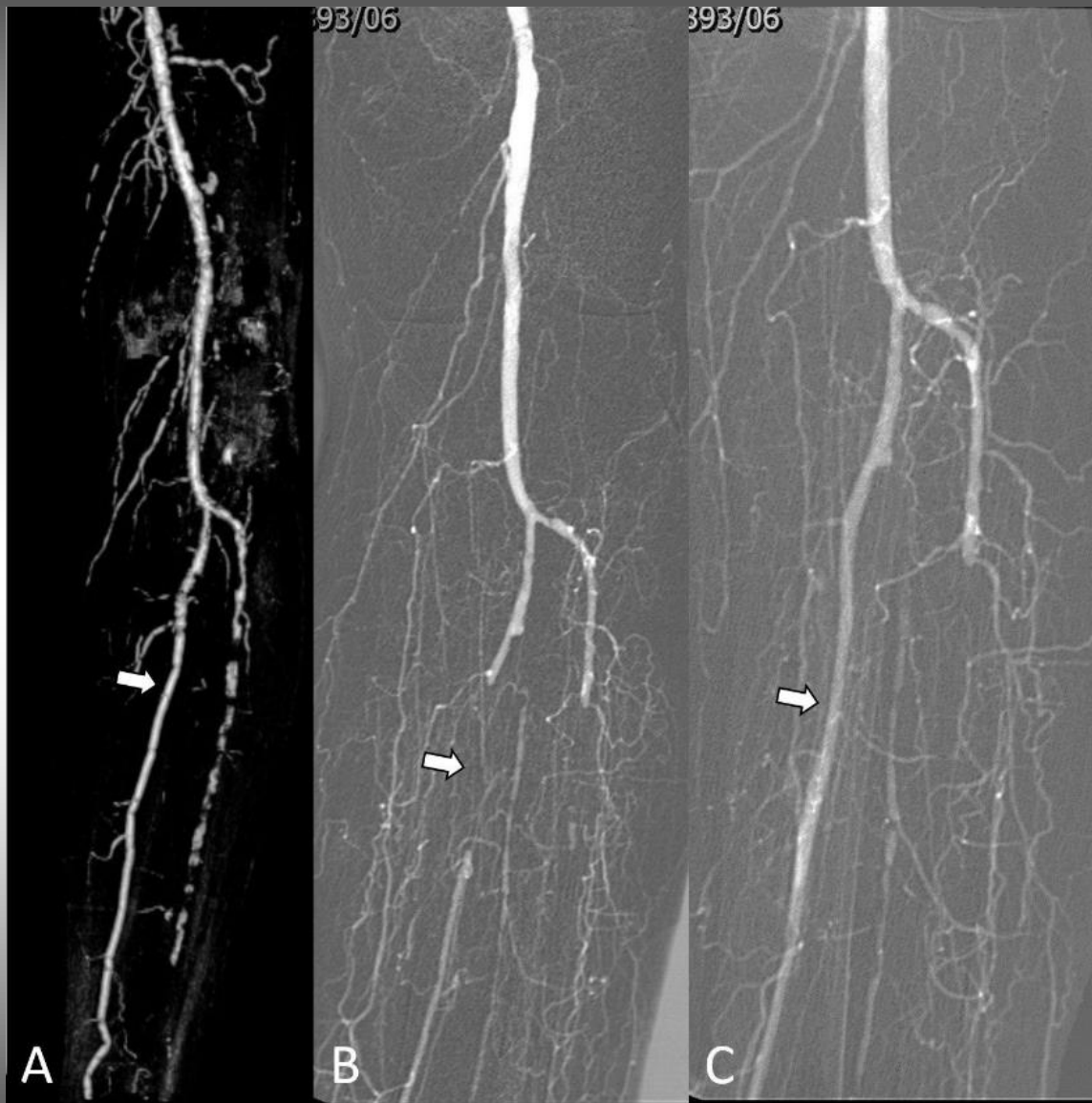


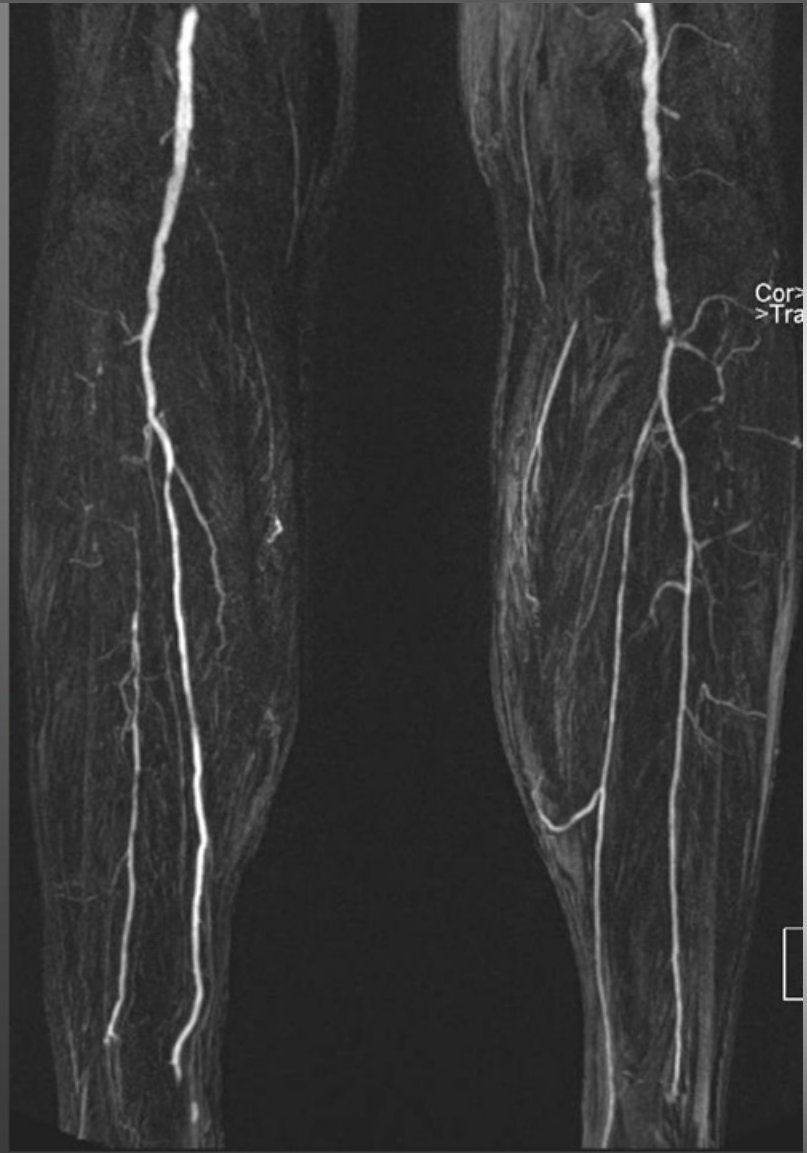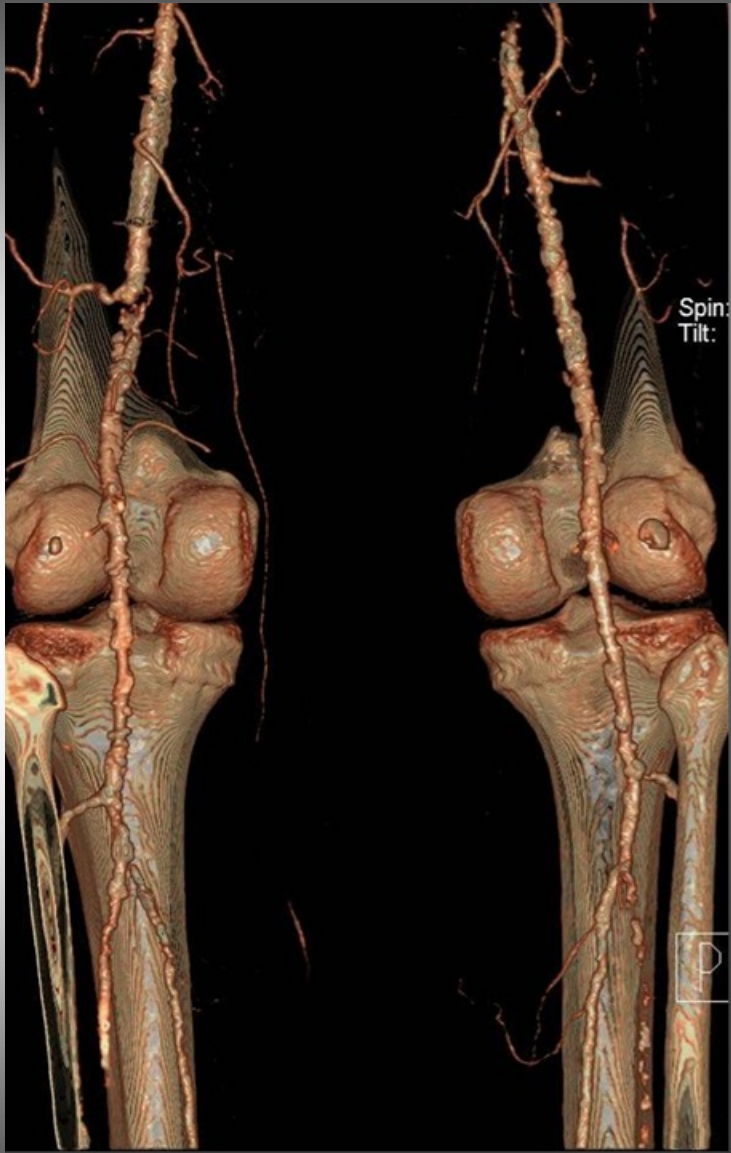






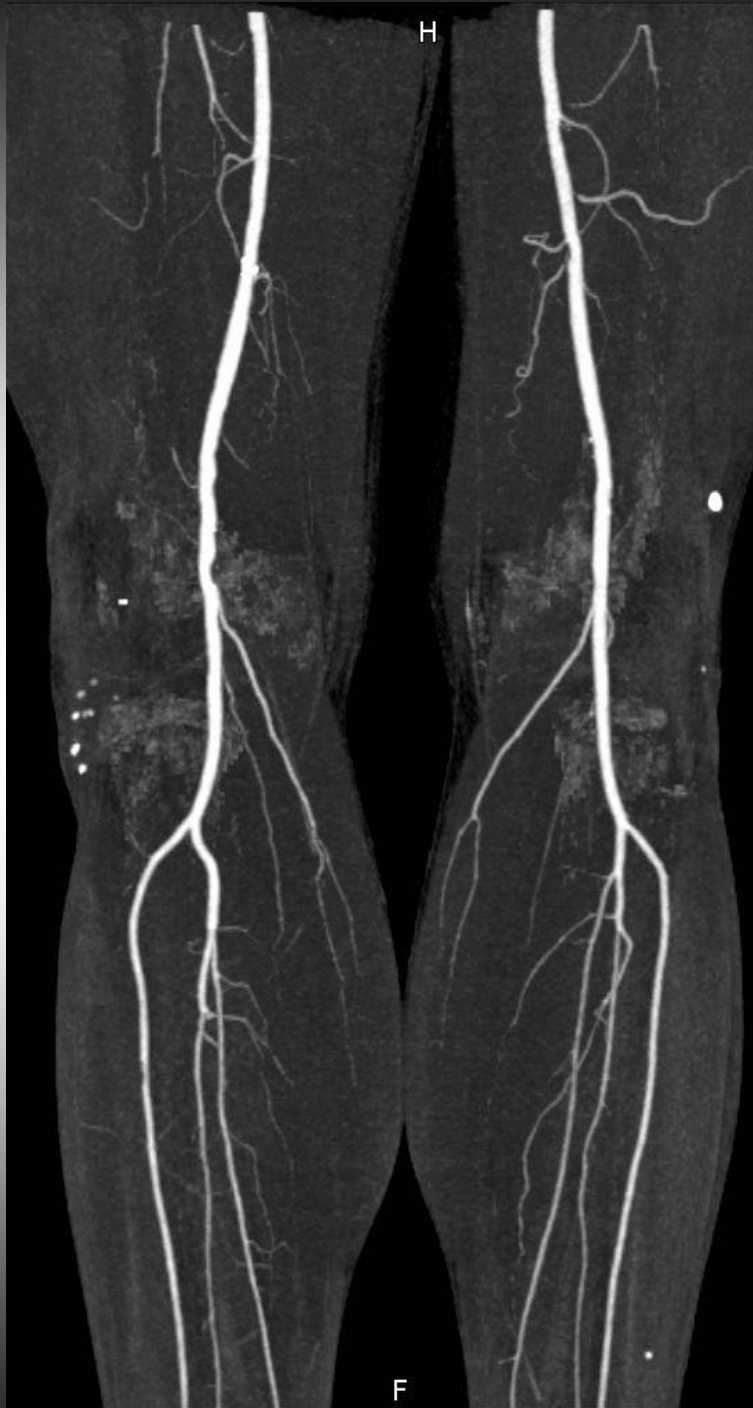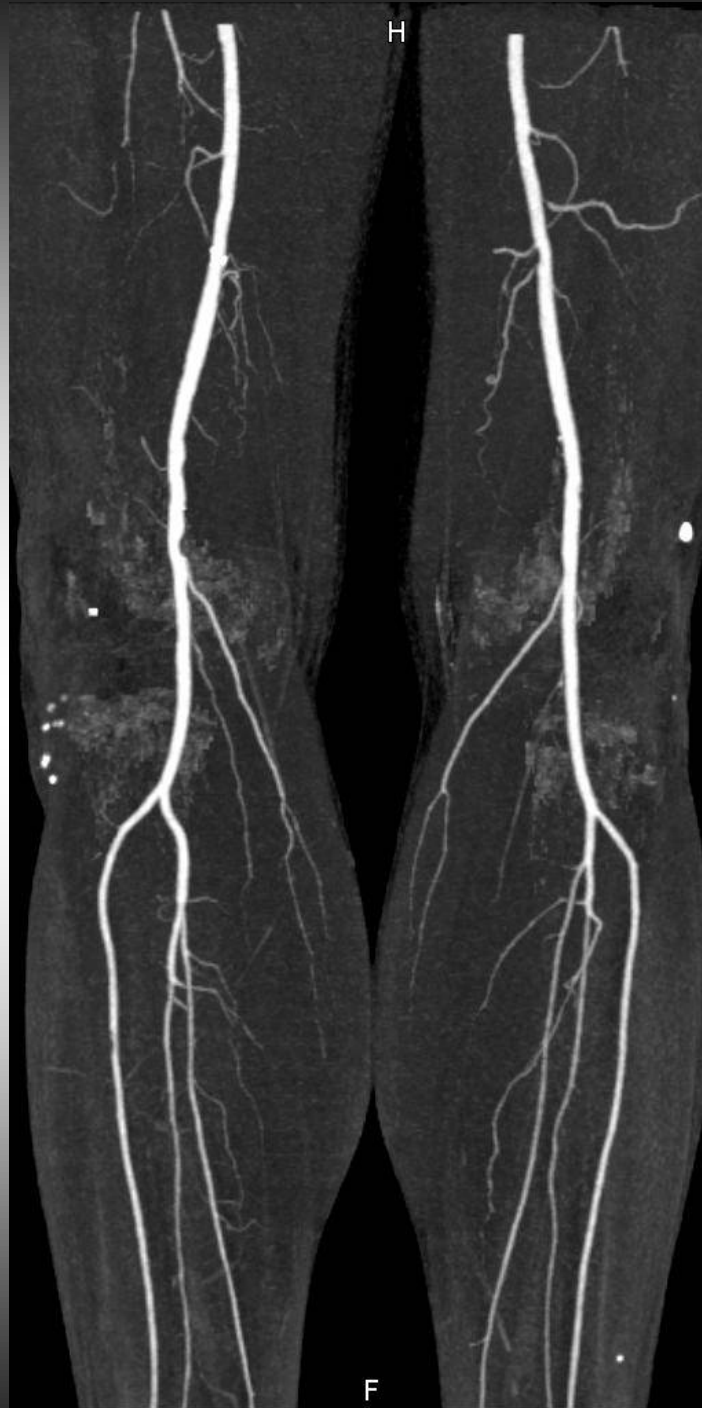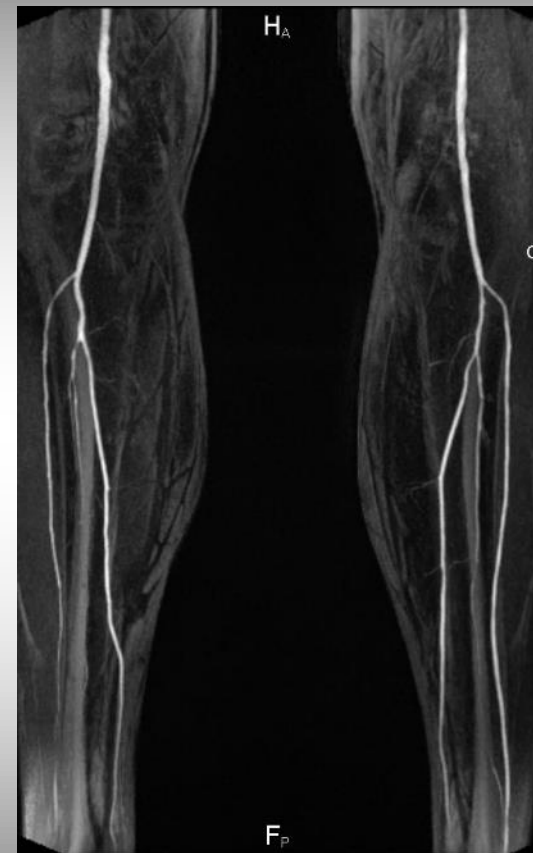
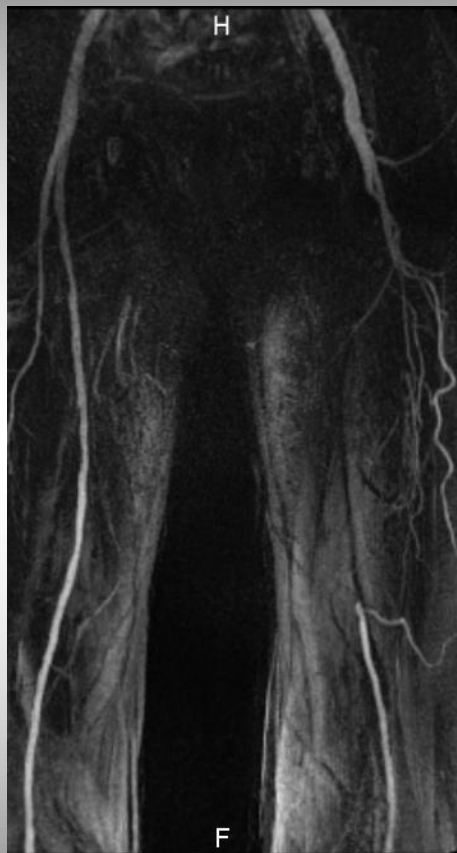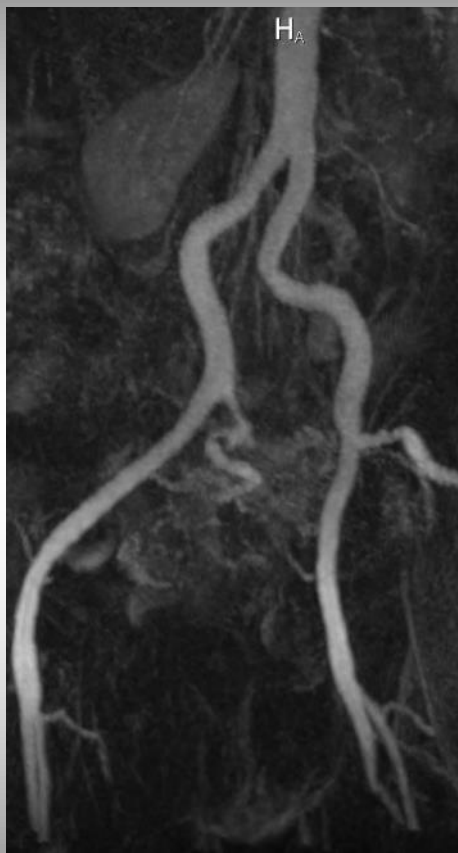













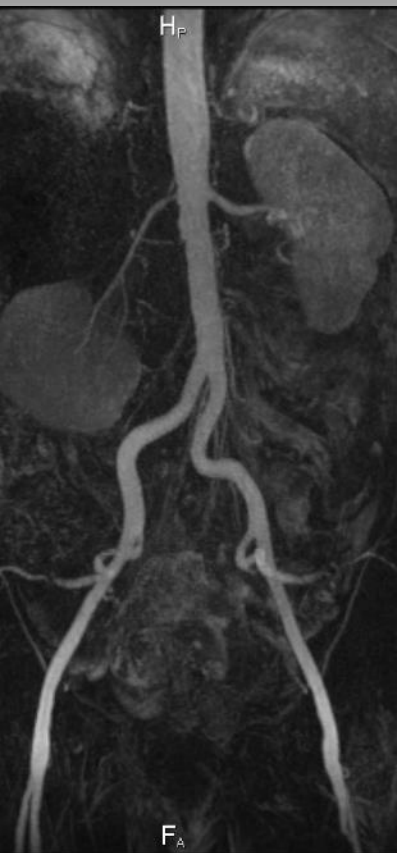
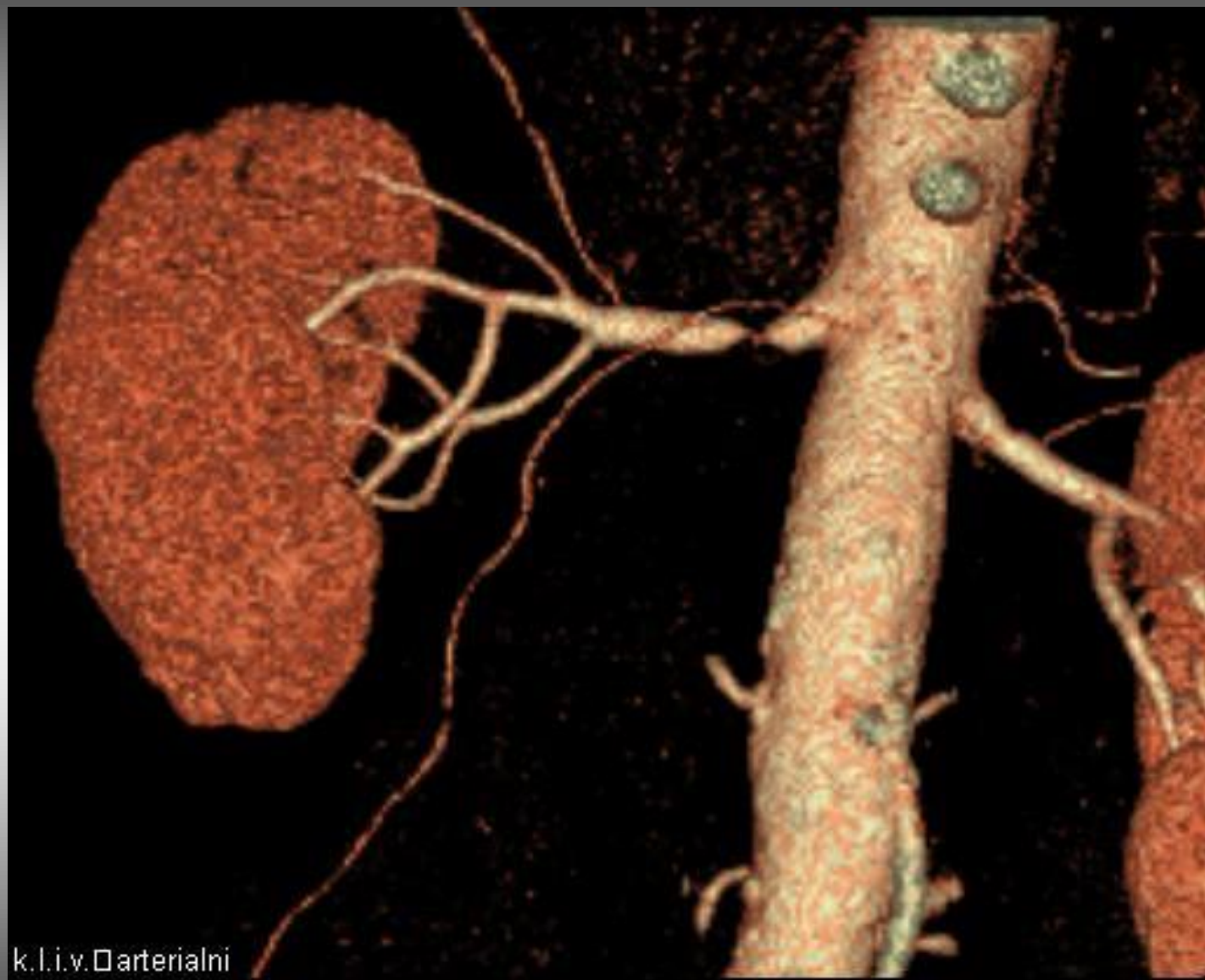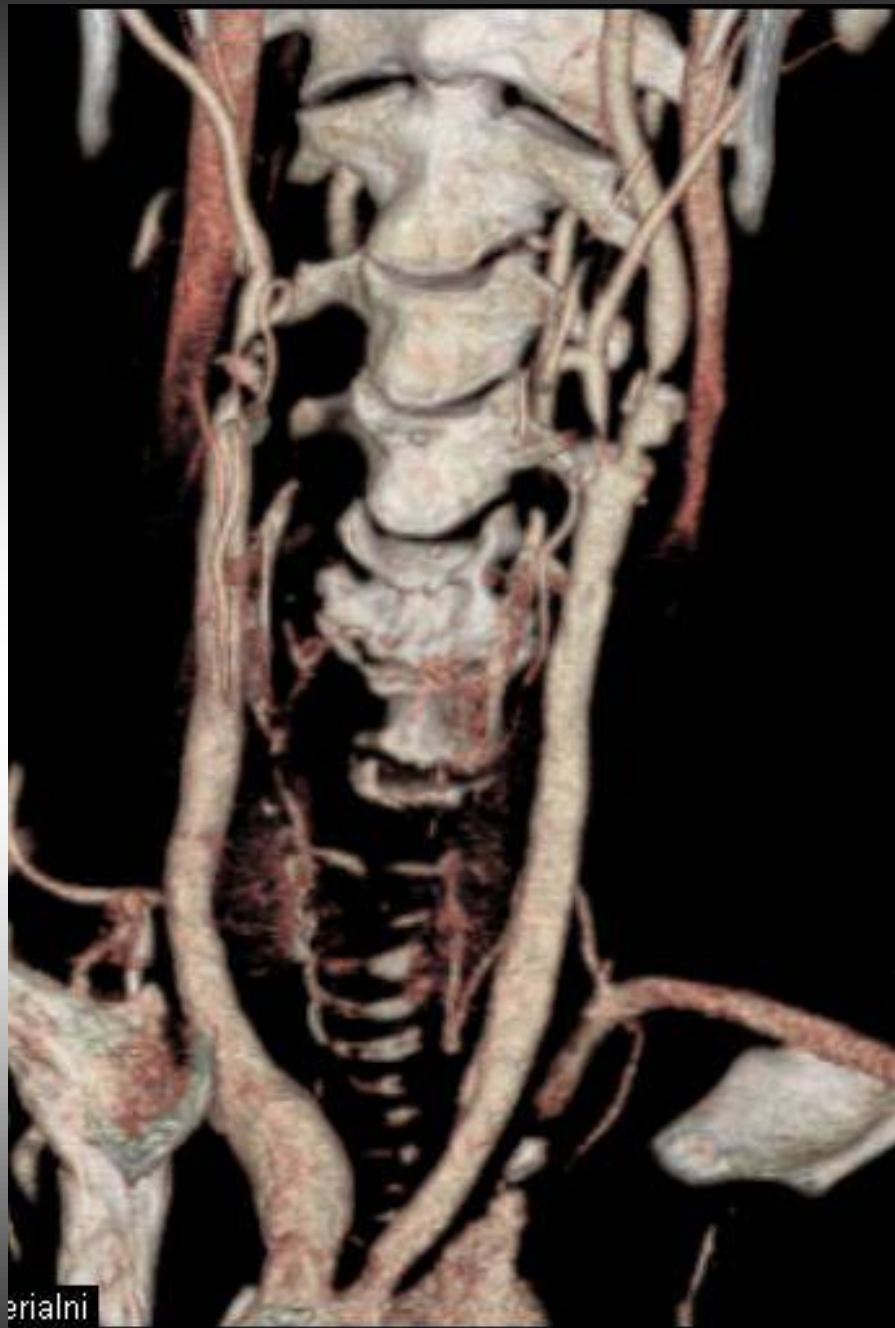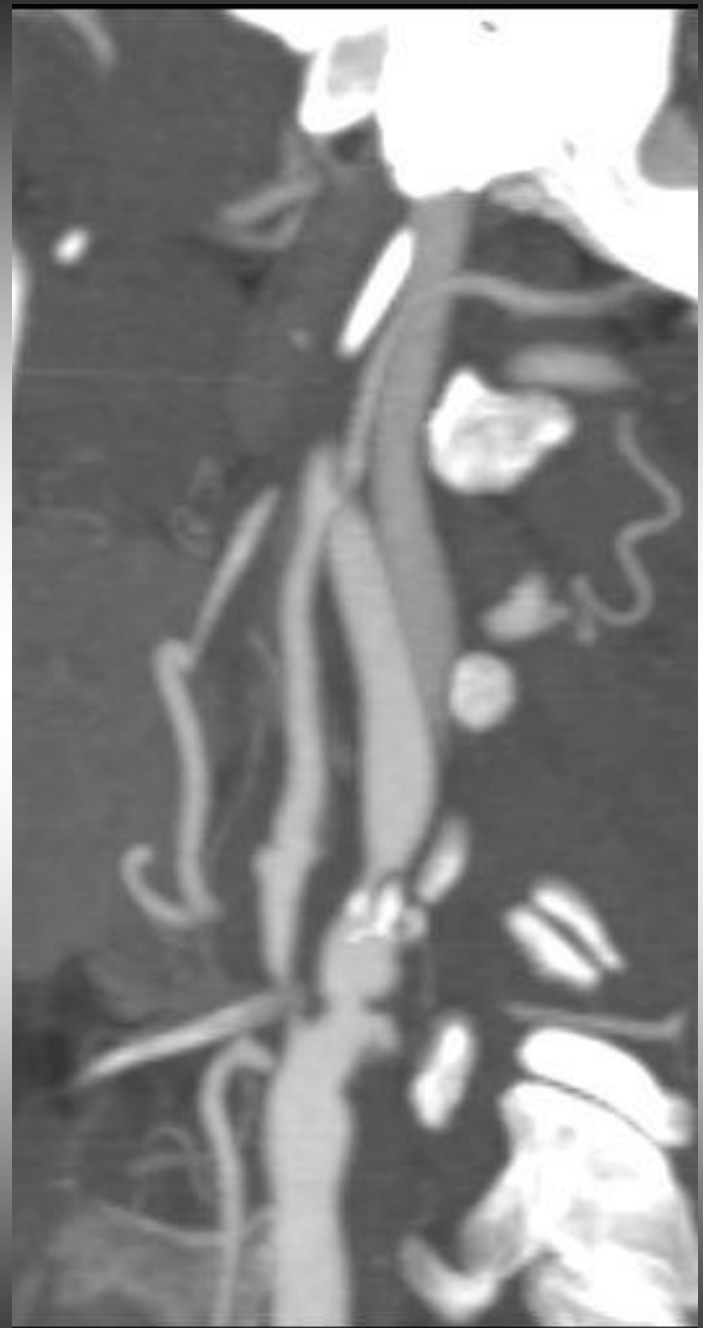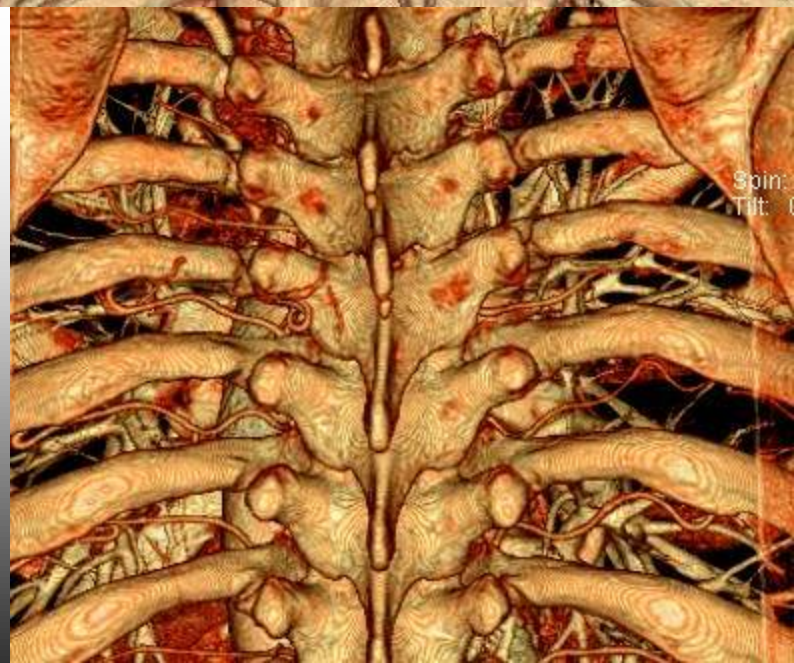
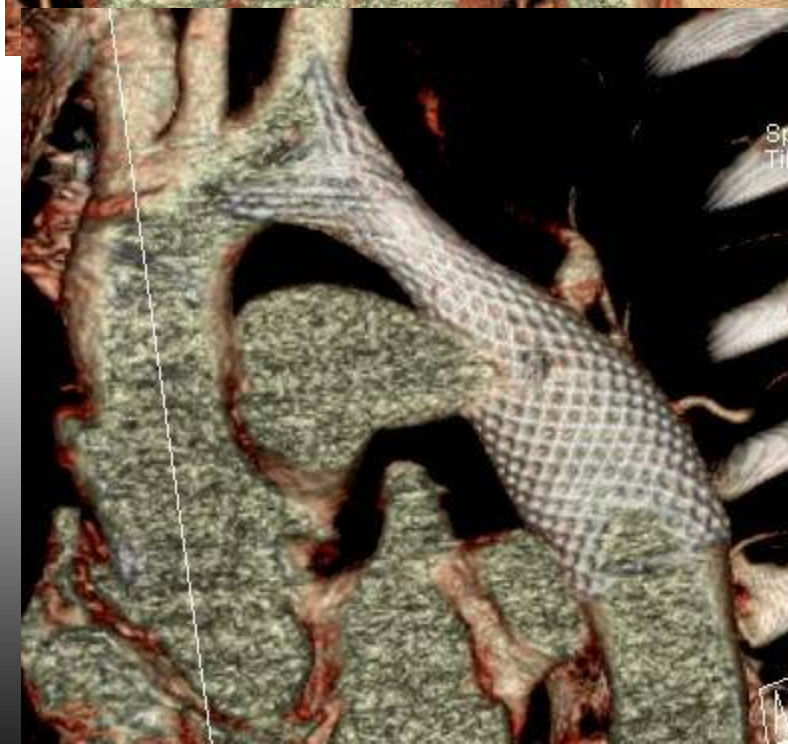
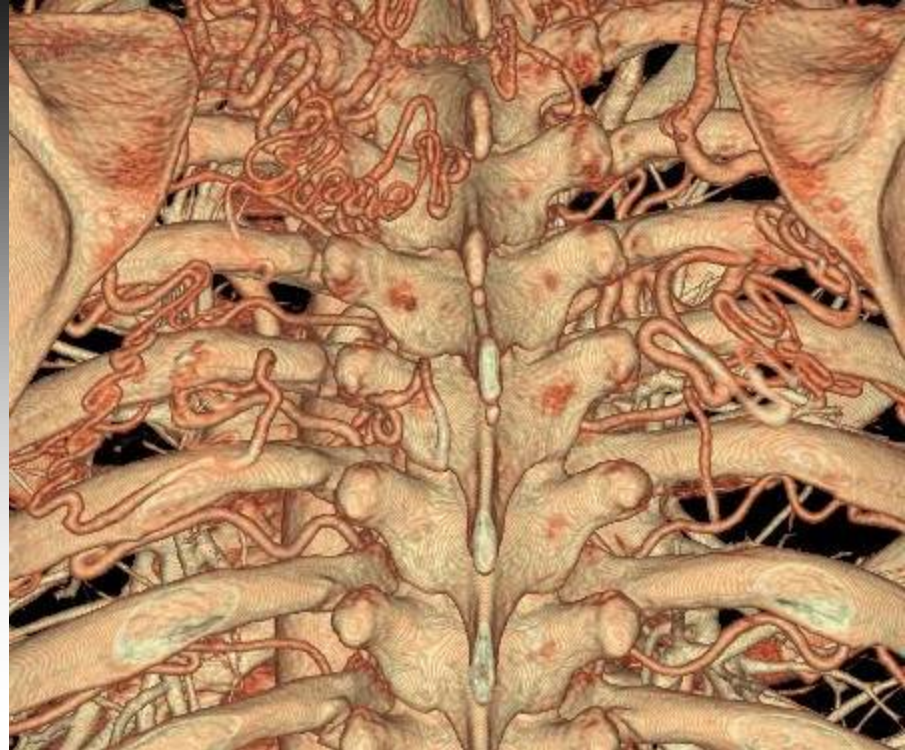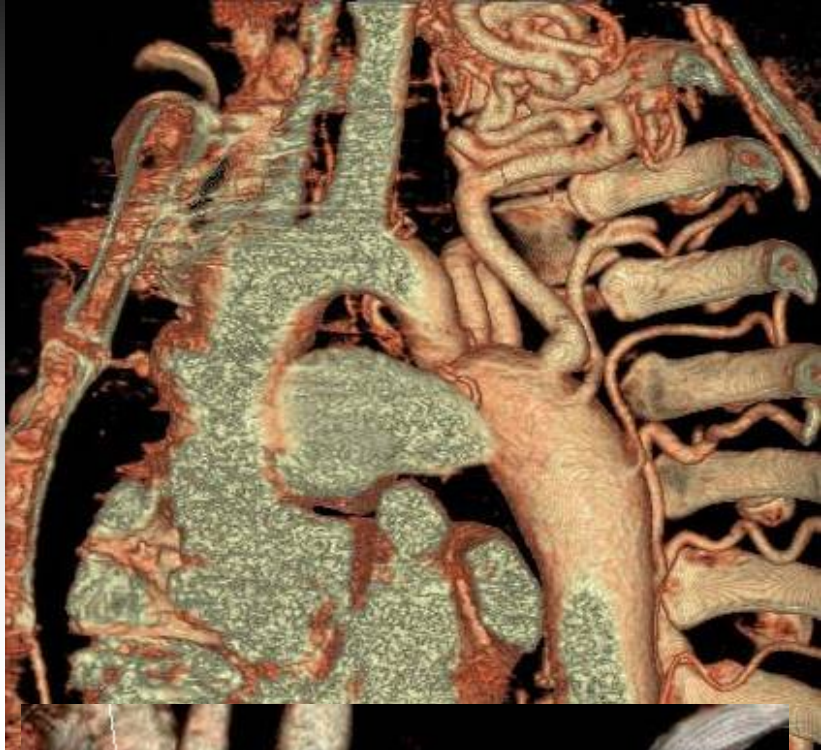k.l.i.v. □ arterialni



erialni

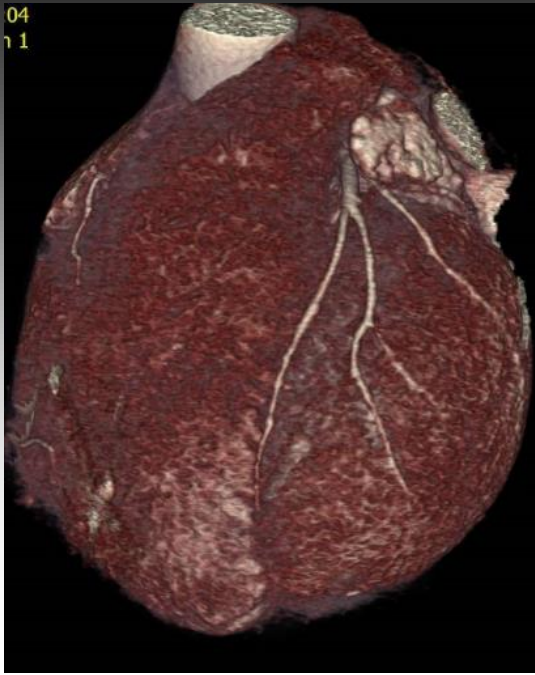




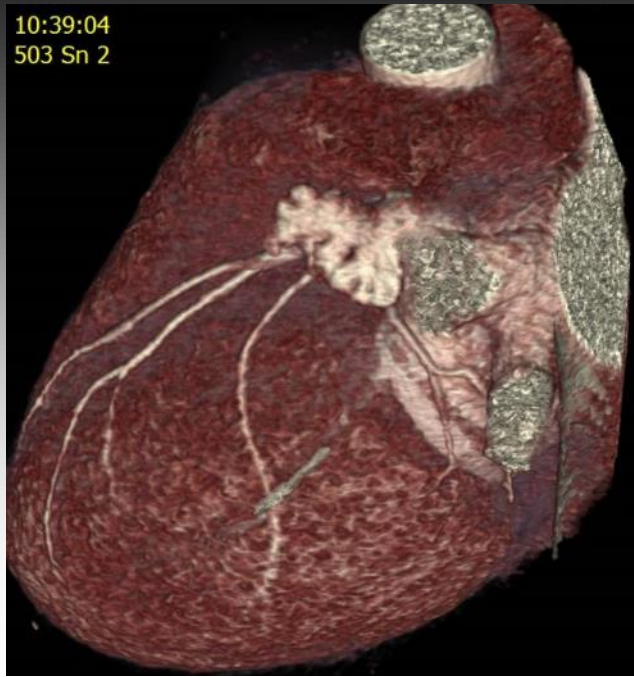



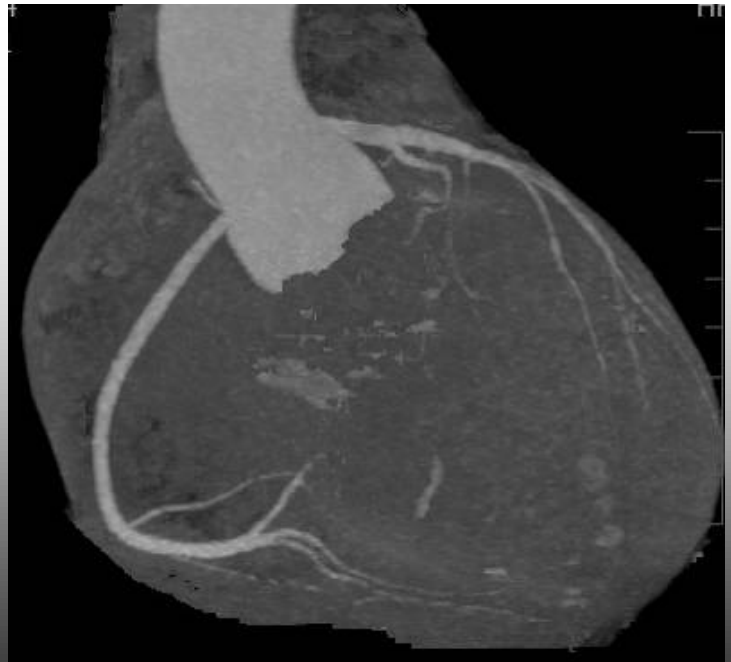
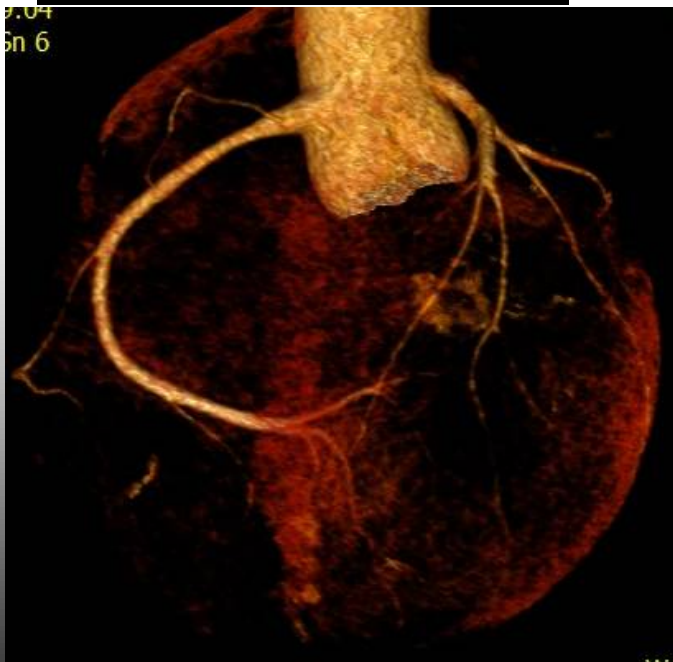04  
n 1



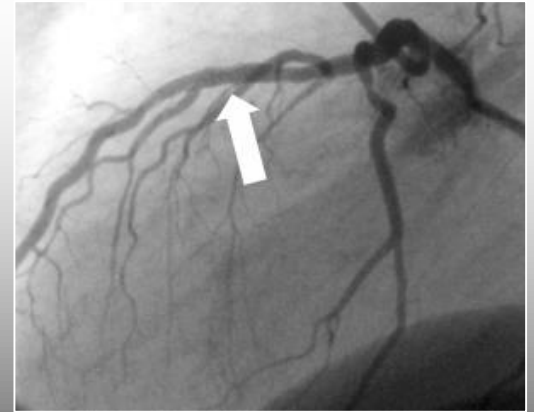
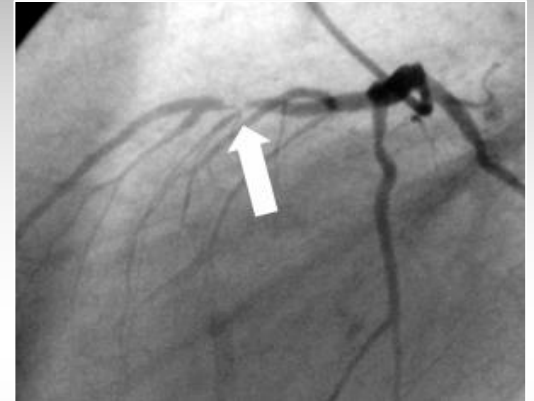
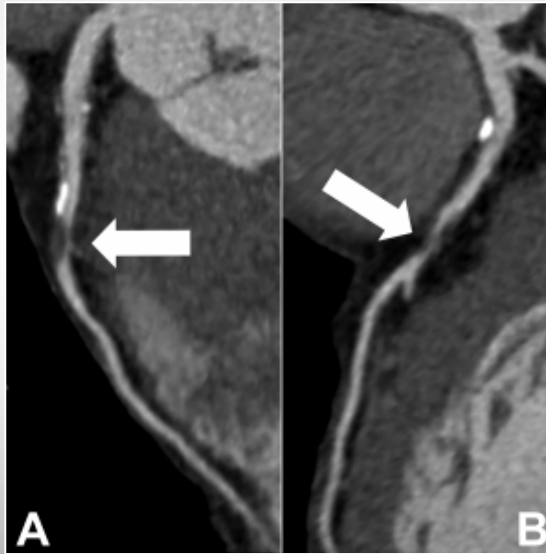
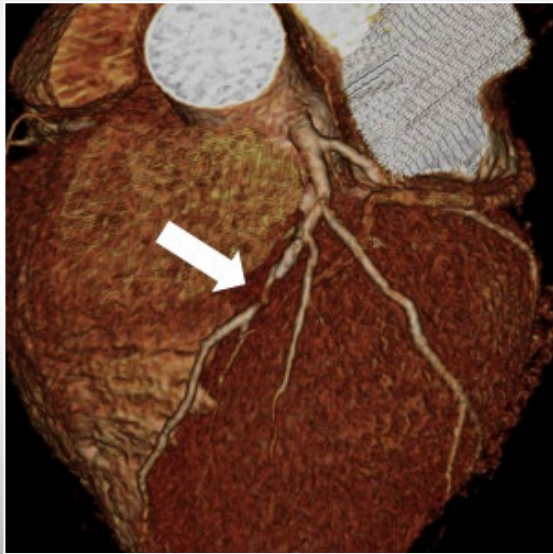10:39:04  
503 Sn 2



9.04  
Sn 6

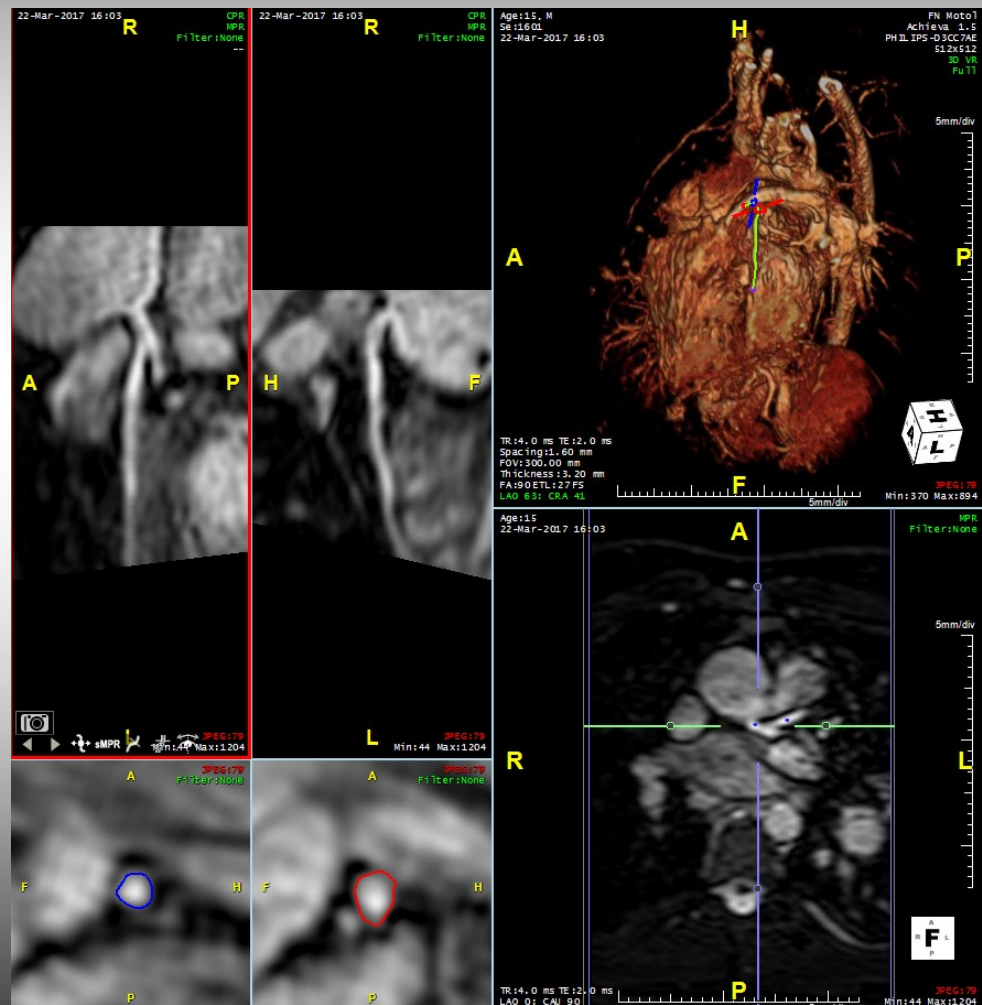


*CTA koronárných tepen  
Významná stenóza R1A  
SKG + P1A*



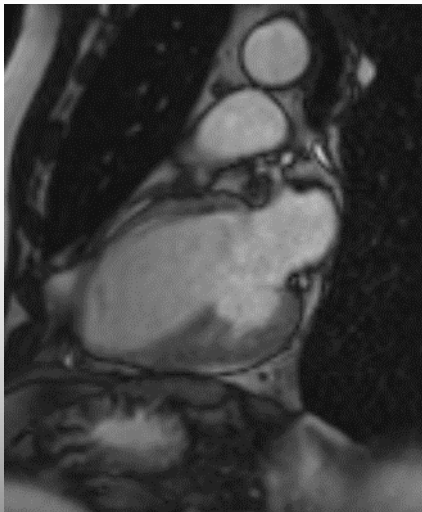
# 3D MR zobrazení koronárních tepen

- Chlapec, 15 let
- Po korekci Fallotovy tetralogie
- SF 90/min

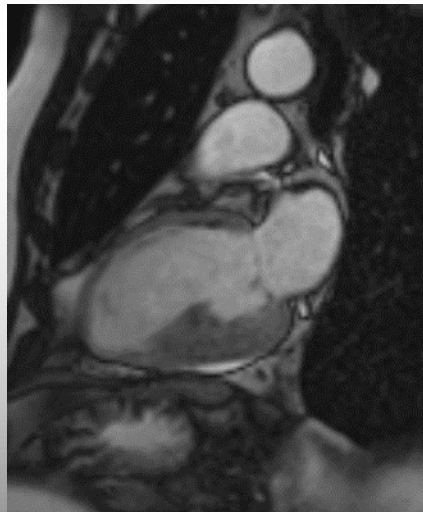

# MR - Infarkt myokardu

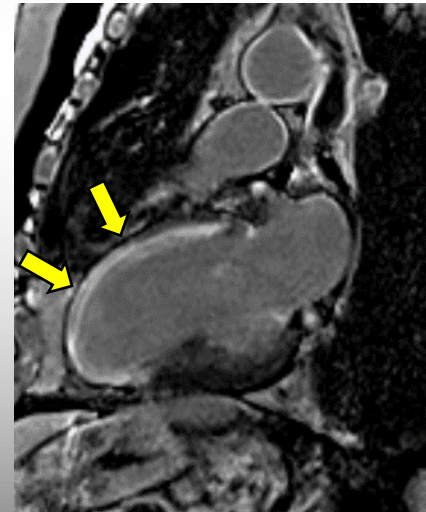
- Chronický stav po IM v povodí RIA s transmurální jizvou přední stěny a hrotu, s akinezou.



Cine: diastola



Cine: systola



Pozdní nasycení jizvy



# *Perspektivy cévní diagnostiky*

- Kvalitnější a levnější sonografická vyšetření
- Vyřešení problémů s kalcifikacemi na CTA
- Snížení množství kontrastní látky pro CTA
- Zvýšení rozlišení MRA
- Nové kontrasty pro MRA
- Kvalitnější CT a MR koronarografie

# *Perspektivy cévních intervencí*

- Další zmenšování instrumentaria, zejména stentgraftů
- Vyřešení uzávěrů místa vpichu
- Biodegradabilní stenty
- Stenty uvolňující farmaka
- Nové rekanalizační metody
- Nové embolizační materiály
- Nové nápady